

## Pure Intraseellar Meningioma Located Under the Pituitary Gland: Case Report

Seung Woo Cha, MD<sup>1</sup>, Dong Woo Park, MD<sup>1</sup>, Choong-ki Park, MD<sup>1</sup>, Young-Jun Lee, MD<sup>2</sup>,  
Seung Ro Lee, MD<sup>2</sup>, Ju Yeon Pyo, MD<sup>3</sup>

Departments of <sup>1</sup>Radiology and <sup>3</sup>Pathology, College of Medicine, Hanyang University, Guri Hospital, Guri 471-701, Korea; <sup>2</sup>Department of Radiology, College of Medicine, Hanyang University, Seoul 133-792, Korea

Most intraseellar meningiomas are located in the subdiaphragmatic and supraglandular region because they originate from the diaphragma sellae. Subglandular meningiomas located under the pituitary gland are extremely rare. Intraseellar meningiomas in the subdiaphragmatic and subglandular region probably originate from the dura in the sellar floor. We report a case of a subglandular meningioma along with a review of the literature.

**Index terms:** *Intracranial meningioma; Intraseellar meningioma; Sellar turcica*

### INTRODUCTION

In 1997, Nozaki et al. (1) described subdiaphragmatic intraseellar meningiomas that originated from the sellar turcica; two of which only originated from the floor of the sellar turcica. Since then, only one case of intraseellar meningioma from the sellar floor has been reported in the English literature (2). The pituitary gland is reported to be covered by two distinct structures: the capsule and dura (3). Although meningiomas can originate from anywhere in the sella turcica, subglandular meningiomas are extremely rare (1). We report a case of subglandular meningioma probably originating from the floor of the sella turcica along with a review of the pituitary fossa anatomy.

Received August 26, 2011; accepted after revision March 15, 2012.

**Corresponding author:** Dong Woo Park, MD, Department of Radiology, College of Medicine, Hanyang University, Guri Hospital, 153 Gyeongchun-ro, Guri 471-701, Korea.

• Tel: (8231) 560-2543 • Fax: (8231) 560-2551

• E-mail: [dwpark@hanyang.ac.kr](mailto:dwpark@hanyang.ac.kr)

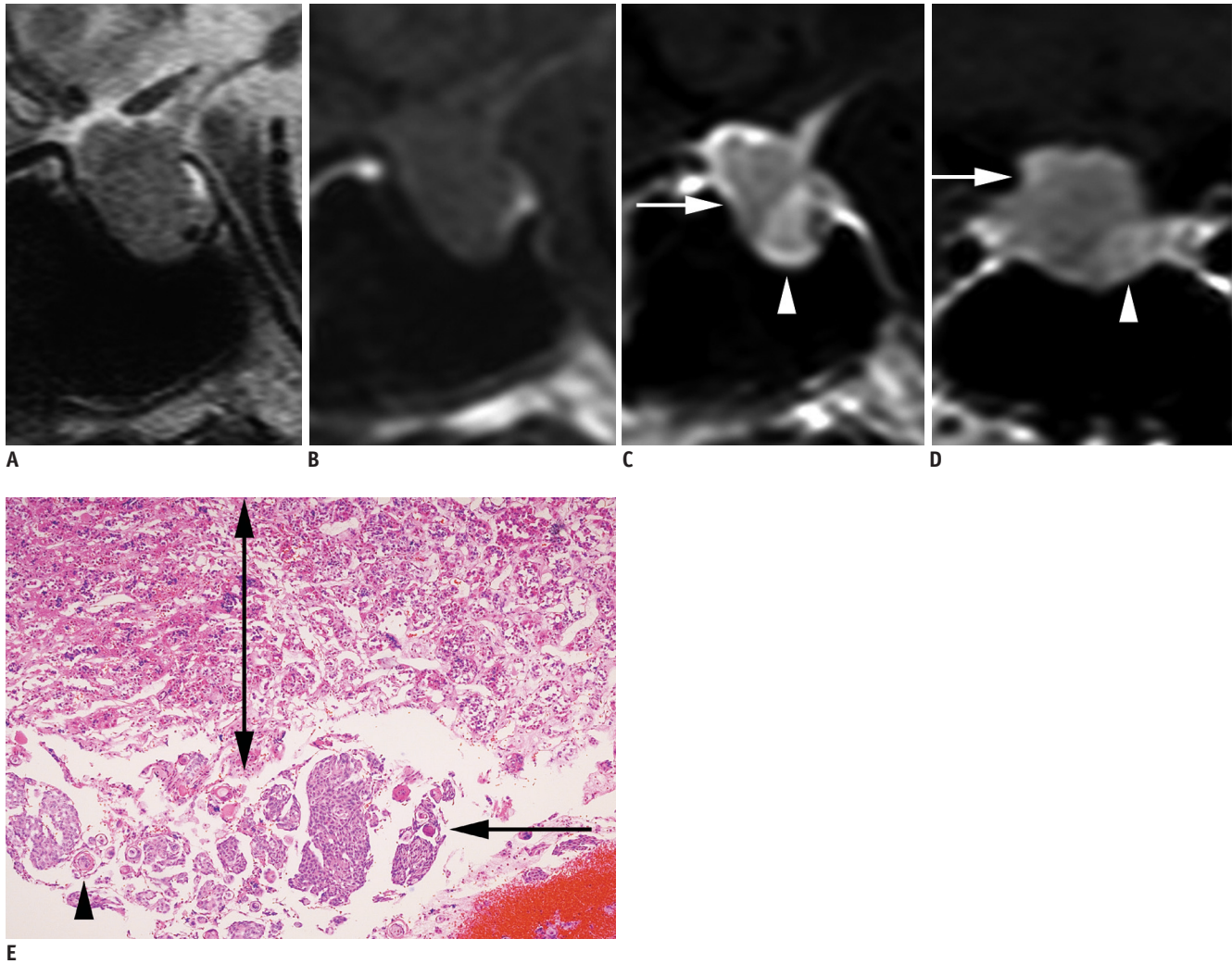
This is an Open Access article distributed under the terms of the Creative Commons Attribution Non-Commercial License (<http://creativecommons.org/licenses/by-nc/3.0>) which permits unrestricted non-commercial use, distribution, and reproduction in any medium, provided the original work is properly cited.

### CASE REPORT

A 57-year-old woman was admitted to our hospital with recent memory disturbance. A magnetic resonance imaging study was performed to evaluate possible vascular dementia.

The imaging revealed an intraseellar mass measuring approximately 1.8 x 1.7 cm with a slightly upward bulge, homogenous isointense signals on T1- and T2-weighted images, and a focal inhomogenous signal on T2-weighted images (Fig. 1A, B). On contrast-enhanced T1-weighted images, the lower portion of the sellar mass was greatly enhanced, and the upper portion, lesser enhanced (Fig. 1C, D). Initially the upper portion was thought to be a pituitary adenoma and the lower portion, normal pituitary gland.

When an endonasal transsphenoidal operation was performed to remove the tumor, a bulging tumor on the sellar floor was observed through the operating window. It appeared as a well-demarcated, friable, yellowish, hard mass. The normal pituitary gland was elevated and shifted to the left anterolateral side by the mass. After the tumor was removed, the diaphragma sellae was identified at the top of the sellar turcica. On histological examination, the low-lying intraseellar lesion was confirmed as a meningioma, while above it was the normal pituitary gland (Fig. 1E).



**Fig. 1. Subgladular meningioma from floor of sellar turcica.**

Sagittal T2- (A) and T1- (B) weighted MR images show intrasellar mass measuring approximately 1.8 x 1.7 cm, with slight suprasellar bulge. Mass shows homogenous isointense signals except for focal inhomogenous signal on T2-weighted image. Contrast enhanced sagittal (C) and coronal (D) T1-weighted MR images shows intrasellar mass with two compartments of different enhancement; upper lesser-enhancing compartment (arrow) is confirmed to be normal pituitary gland and lower greater-enhancing compartment (arrowhead), as meningioma. E. Photomicrograph (Hematoxylin & Eosin staining, x 100) shows mixture of acidophils and basophils in upper region (up-down arrow), corresponding to normal pituitary gland tissue. lower region is confirmed to be meningioma (arrow), containing whirls of cells (arrowhead).

## DISCUSSION

In 1969, Hardy and Robert (4) described a separate type of intrasellar meningioma originating from the inferior aspect of the diaphragma sellae. In 1985, Al-Mefty et al. (5) proposed that diaphragmatic meningiomas and a tuberculum sellae meningiomas were separate entities. In 1995, Kinjo et al. (6) classified diaphragm sellae tumors according to their site of origin from the diaphragm: type A originated from the upper leaf of the diaphragma sellae anterior to the pituitary stalk; type B from the upper leaf of the diaphragma sellae posterior to the pituitary stalk; and type C from the inferior leaf of the diaphragma sellae.

In 1997, Nozaki et al. (1) summarized observations in the literature on 18 operatively confirmed pure subdiaphragmatic intrasellar meningiomas originating from the dura of the sella turcica. They included type C diaphragma sellae meningiomas according to Kinjo's classification and intrasellar meningiomas from the other side of the sella, such as the floor and anterior or lateral wall. They established the origin of 9 meningiomas; 6 from the inferior leaf of the diaphragma sellae (the same as type C diaphragma sellae meningiomas), 2 from the floor of the sella turcica, and only one from the anterior wall of the sella turcica. One further example from the floor of the sella has been reported since then (2). To the best of our knowledge,

only three cases of intrasellar meningiomas originating from the floor of sella turcica have been reported.

It is important to differentiate a diaphragm sellae meningioma from a pituitary macroadenoma because they require different surgical approaches. Cappabianca et al. (7) emphasized that, most of the intra- and suprasellar macroadenomas could be approached by the transsphenoidal route, while diaphragm sellae meningiomas might require a craniotomy. For diaphragm sellae meningiomas, the transcranial-transsphenoidal approach is preferred for a type C meningioma and the cranio-orbital approach for type A and type B meningiomas (6). On the other hand, the transsphenoidal approach is advocated for all subdiaphragmatic meningiomas (8), or should be tried first, irrespective of whether the lesion is a meningioma or a pituitary adenoma; even if it has a small suprasellar extension (2).

According to Cappabianca et al. (7), it is essential for the diagnosis of type C meningiomas that the diaphragm sellae be displaced upwards with the normal pituitary gland visible below. Our case also showed upward bulging of the complex of the diaphragm sellae and pituitary gland, with the meningioma located below the pituitary gland with a broad-based attachment to the sellar floor.

The pituitary gland is reported to be covered by two distinct structures; a capsule and the dura in the pituitary fossa (3). At each inferolateral edge of the pituitary fossa, the thick dura of the inferior wall splits into two thinner layers that form a Y shape. One of the arms of the Y forming the lateral wall of the pituitary fossa is directed superiorly, while the other arm continues as the sphenoidal part of the medial wall of the cavernous sinus and extends to the lateral limit of the sinus (3). Meningiomas can originate from any part of the dura in the sella turcica.

It is difficult to differentiate intrasellar meningiomas from intrasellar tumors, which can include pituitary adenoma, pituicytomas, intrasellar germinomas, craniopharyngiomas, aneurysms, and metastases. Calcifications are a feature of intrasellar meningiomas, craniopharyngiomas, and aneurysms, but they are not typical features of adenomas. Necrotic or cystic changes can be found in most types of intrasellar tumors except for meningiomas. Intrasellar

meningiomas and aneurysms are generally more strongly enhanced than normal pituitary gland. Meanwhile, imaging findings on the angioarchitecture of aneurysms allow them to be differentiated from other tumorous lesions.

The intrasellar mass in our case was treated by the transsphenoidal approach because our preoperative diagnosis was a pituitary adenoma. During the operation, the lower part of the intrasellar mass was found to be subglandular meningioma following a frozen biopsy, which was successfully removed, while leaving intact normal pituitary gland in the upper part of the intrasellar mass.

In conclusion, intrasellar subglandular meningiomas are extremely rare, which are easily confused with pituitary macroadenomas. They probably originate from the dura in the sellar floor, while most intrasellar meningiomas that are located in the subdiaphragmatic and supraglandular area originate from the diaphragm sellae. We report a case of intrasellar and subglandular meningioma along with a review of the literature.

## REFERENCES

1. Nozaki K, Nagata I, Yoshida K, Kikuchi H. Intrasellar meningioma: case report and review of the literature. *Surg Neurol* 1997;47:447-452; discussion 452-454
2. Kudo H, Takaishi Y, Minami H, Takamoto T, Kitazawa S, Maeda S, et al. Intrasellar meningioma mimicking pituitary apoplexy: case report. *Surg Neurol* 1997;48:374-381
3. Peker S, Kurtkaya-Yapici O, Kiliç T, Pamir MN. Microsurgical anatomy of the lateral walls of the pituitary fossa. *Acta Neurochir (Wien)* 2005;147:641-648; discussion 649
4. Hardy J, Robert F. [A meningioma of the sella turcica, subdiaphragmatic variety. Exeresis through the transsphenoidal route]. *Neurochirurgie* 1969;15:535-543
5. Al-Mefty O, Holoubi A, Rifai A, Fox JL. Microsurgical removal of suprasellar meningiomas. *Neurosurgery* 1985;16:364-372
6. Kinjo T, al-Mefty O, Ciric I. Diaphragm sellae meningiomas. *Neurosurgery* 1995;36:1082-1092
7. Cappabianca P, Cirillo S, Alfieri A, D'Amico A, Maiuri F, Mariniello G, et al. Pituitary macroadenoma and diaphragm sellae meningioma: differential diagnosis on MRI. *Neuroradiology* 1999;41:22-26
8. Civit T, Marchal JC, Pinelli C, Auque J, Hepner H. [Meningiomas of the sellar diaphragm. Apropos of 4 cases]. *Neurochirurgie* 1997;43:21-26; discussion 26-27