

영양 혈관 색전술 후 완전 절제에 성공한 종격동 내 과혈관성 염증성 가성종양 1예

강하나¹ · 신은정¹ · 나위진¹ · 윤기보² · 송순영² · 전석철² · 이준호³ · 정원상³ · 장기석⁴ · 이영호¹

한양대학교 의과대학 ¹소아과학교실, ²영상의학과학교실, ³흉부외과학교실, ⁴병리학교실

A Hypervascular Inflammatory Myofibroblastic Tumor in the Mediastinum Resected Completely Following Embolization of the Feeding Vessels

Ha-na Kang, M.D.¹, Eun-Jung Shin, M.D.¹, Wee Jin Rah, M.D.¹, Kibo Yoon, M.D.², Soon-Young Song, M.D.², Seok Chol Jeon, M.D.², Jun Ho Lee, M.D.³, Won-Sang Jung, M.D.³, Kiseok Jang, M.D.⁴ and Young-Ho Lee, M.D.¹

Departments of ¹Pediatrics, ²Radiology, ³Thoracic and Cardiovascular Surgery, ⁴Pathology, Hanyang University College of Medicine, Seoul, Korea

Inflammatory myofibroblastic tumors (IMTs) are rare tumors of intermediate malignant potential that can occur anywhere in the body. We describe an interesting case of a hypervascular IMT in the mediastinum that could be resected completely following embolization of the feeding vessels. A 17-month-old girl with complaints of cough and fever for 3 months was referred to our hospital. Computed tomography (CT) scan showed a large mass in the right hemithorax that shifted the mediastinum to the left. Primary excision was considered but not performed because there was very active capsule wall bleeding due to the hypervascular tumor. After embolization of the feeding vessels, successful complete resection was carried out. Approximately 6 weeks after the operation, follow-up CT scan showed no evidence of recurrent disease. Preoperative embolization is a good option for performing complete resection of hypervascular IMTs that could reduce the recurrence rate.

pISSN 2233-5250 / eISSN 2233-4580
<http://dx.doi.org/10.15264/cpho.2015.22.2.176>

Clin Pediatr Hematol Oncol
2015;22:176~180

Received on June 29, 2015
Revised on July 8, 2015
Accepted on August 15, 2015

Corresponding Author: Young-Ho Lee
Department of Pediatrics, Hanyang University College of Medicine, 222-1, Wangsimni-ro, Seongdong-gu, Seoul 04763, Korea
Tel: +82-2-2290-8383
Fax: +82-2-2297-2380
E-mail: cord@hanyang.ac.kr

Key Words: Inflammatory pseudotumor, Mediastinal neoplasms, Therapeutic embolization

Introduction

Inflammatory myofibroblastic tumors (IMT) are rare tumors of intermediate malignant potential that can occur anywhere in the body [1]. Approximately 35% of IMTs occur before 15 years of age [2]. Although initially thought to be benign processes, subsequent studies have shown

IMTs to be neoplastic with the ability to recur locally and to metastasize [3]. IMTs have also been known as plasma cell granulomas, fibrous histiocytomas, xanthogranulomas, inflammatory pseudotumors, and atypical fibromyxoid tumors because of their variable cellular constituents [4].

The primary treatment for IMTs is complete surgical excision, which is curative [5]. However, some tumors are not amenable to surgical excision, or excision may be asso-

ciated with high morbidity [6]. Here we report the case of a 17-month-old patient with IMT of the mediastinum successfully treated by complete resection after embolizing the feeding vessels.

Case Report

A 17-month-old girl who had complained of cough and fever for 3 months was referred to our hospital in April, 2014. Physical examination revealed decreased lung sound in the right lobe. The liver tip, but not the spleen, was palpated just below the right costal margin. Routine blood test revealed hemoglobin 5.5 g/dL, mean corpuscular volume 64.7 fL, red cell distribution width 20.9%, white blood cell 16,100 / μ L, platelet 724,000 / μ L, erythrocyte sedimentation rate 45 mm/hr, c-reactive protein 11.6 mg/dL, serum iron 14 μ g/dL, total iron-binding capacity 231 μ g/dL, ferritin 149.2 ng/mL, and reticulocyte index 0.55. Peripheral blood morphology showed microcytic hypochromic anemia, compatible with the anemia of chronic disease. Plain chest radiograph showed a homogenous opacity occupying the entire right hemithorax. On computed tomography (CT) scan, there was a large mass in the right hemithorax that shifted the mediastinum to the left (Fig. 1).

During exploratory surgery, a huge mass was found in the right thorax. Its upper margin was the azygos vein and its lower margin, the diaphragm. It was strongly adherent to the vertebrae and posterior ribs. It was fed mainly by vessels from the sixth to tenth right posterior intercostal arteries and the bronchial artery at the fourth rib level.

Primary excision was considered but not performed because capsule wall bleeding was very active due to the hypervascular tumor, and only a wedge biopsy was performed. Microscopic examination revealed a proliferation of regular spindle cells arrayed in fascicles, admixed with lymphocytes, plasma cells and eosinophils. Immunohistochemical staining was positive for smooth muscle actin, leukocyte common antigen, desmin and vimentin (Fig. 2), but negative for anaplastic lymphoma kinase. Based on these data, the diagnosis of IMT was retained. Thereafter abdominal CT scan was performed to investigate another lesion, which showed negative finding.

To perform complete resection, we decided to embolize the feeders to achieve preoperative control of the vascularity of the mass. Interventional procedures were carried out in the angiographic unit under general anesthesia. Initially we obtained an angiogram through the right femoral access by use of a 4-Fr pig-tail and Davis catheters (Terumo, Tokyo, Japan). It revealed a large hypervascular mass in the right chest with feeders coming from multiple right intercostal and right lateral thoracic arteries. After selecting each feeder with a microcatheter (Progreat [Terumo, Tokyo, Japan]), it was embolized with polyvinyl alcohol particles of 150-250 micrometer (Contour PVA Embolization Particles, Boston Scientific, MA, USA). The procedure was terminated after confirming much decreased vascularity on a post-embolization angiogram (Fig. 3). A surgical approach was made 48 hours later through the sixth right intercostal space previously used for the surgical biopsy. Although the tumor was not reduced, its bleeding tendency

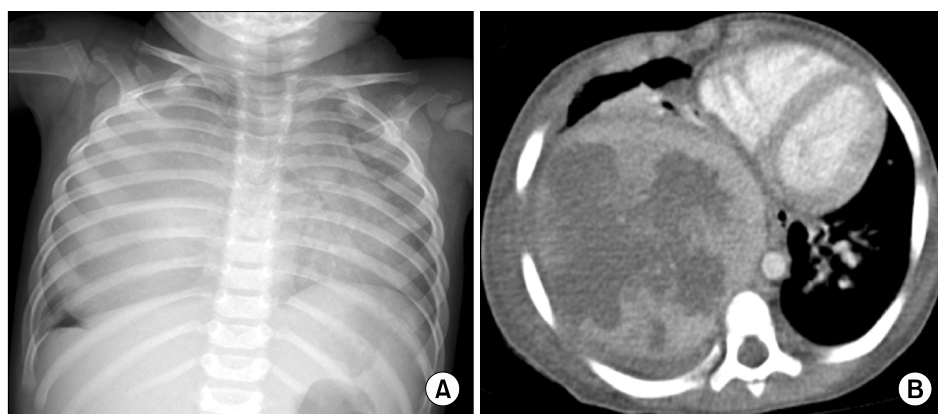


Fig. 1. (A) Plain chest radiograph showing a homogenous opacity occupying the entire right hemithorax. (B) On a chest CT scan, there is a large mass in the right hemithorax that shifts the mediastinum to the left.

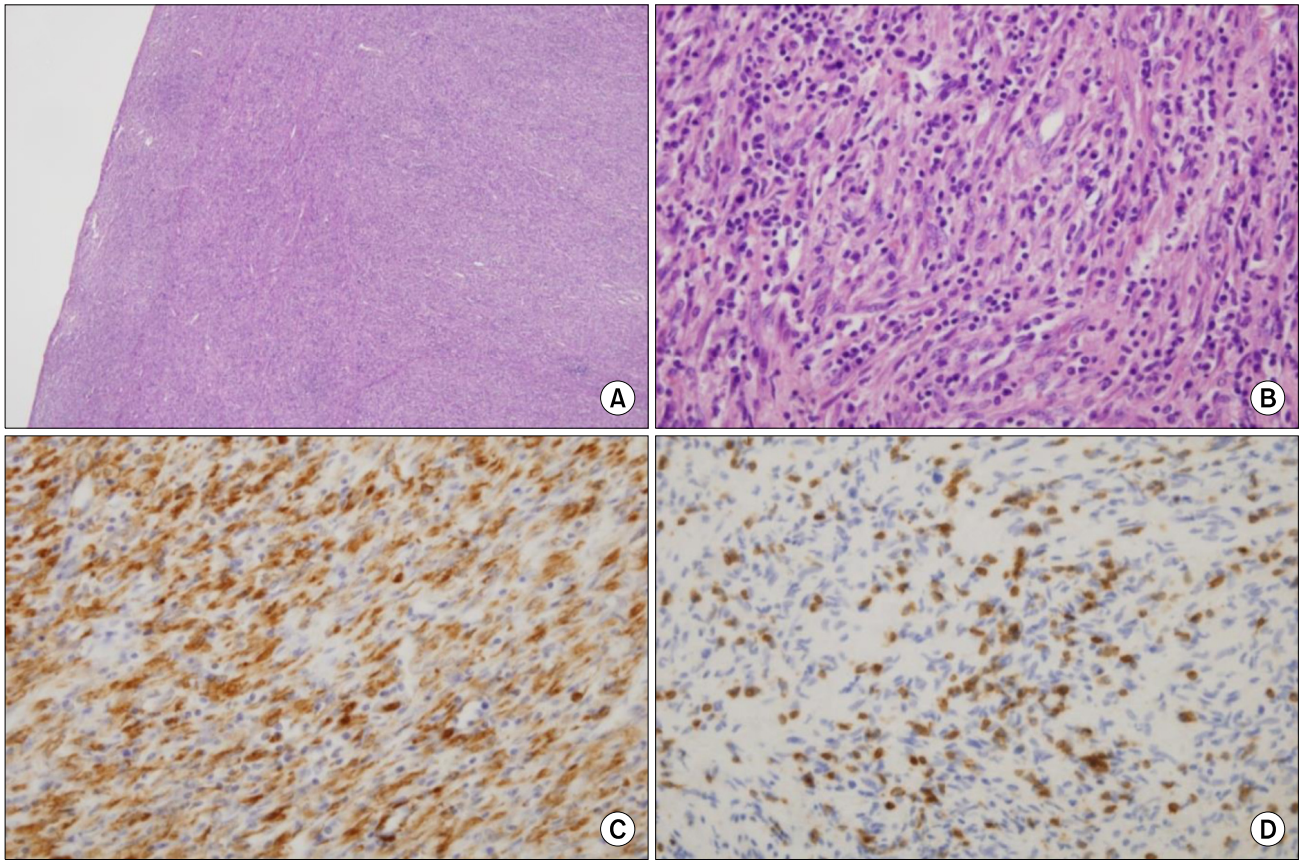


Fig. 2. Hematoxylin and eosin staining of the inflammatory myofibroblastic tumor showing an admixture of spindle-shaped and ovoid cells with a prominent inflammatory infiltrate. $\times 40$ (A) and $\times 400$ (B). Immunohistochemical staining shows reactivity for smooth muscle actin (C) and leukocyte common antigen (D).

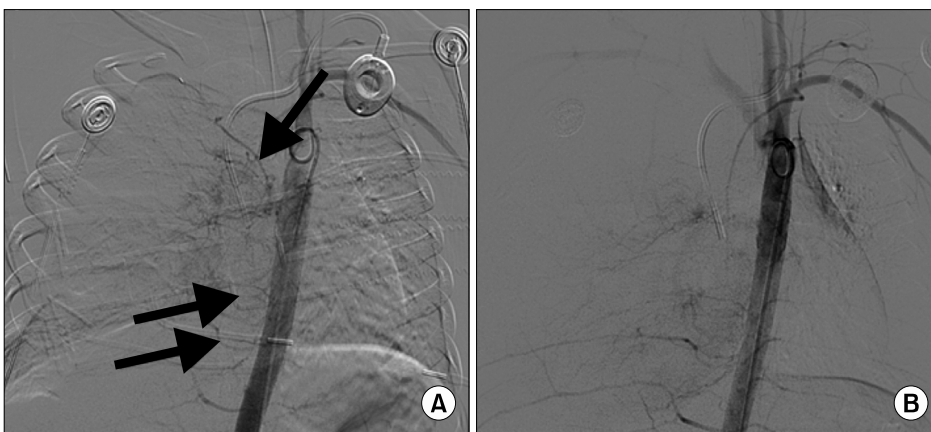


Fig. 3. (A) Thoracic aortography showing the hypervascular mass, which is supplied by multiple right intercostal arteries (arrows). (B) Aortography obtained after embolization of the feeders shows much decreased vascularity.

was less than before, and complete surgical resection was carried out successfully.

Grossly, the tumor was well demarcated, grayish white, solid, measuring 11.5×7.5×6.7 cm, and weighing 238 g. In section, the cut surface had a grayish tan homogeneous

and partly whorled appearance with focal necrosis and hemorrhage (Fig. 4).

After extirpation of the mass, a CT scan revealed an enhancing lesion on the mediastinal side of the right lower lung zone. This seemed to be a residual atelectasis or

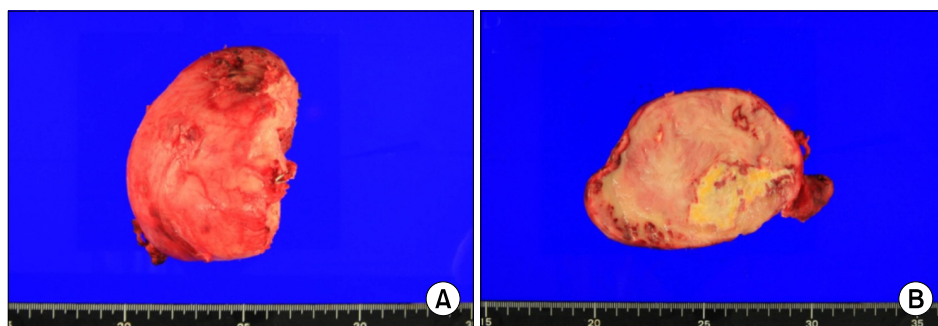


Fig. 4. (A) Gross appearance of the inflammatory myofibroblastic tumor. (B) In section, the cut surface has a grayish tan homogeneous and partly whorled appearance with focal necrosis and hemorrhage.

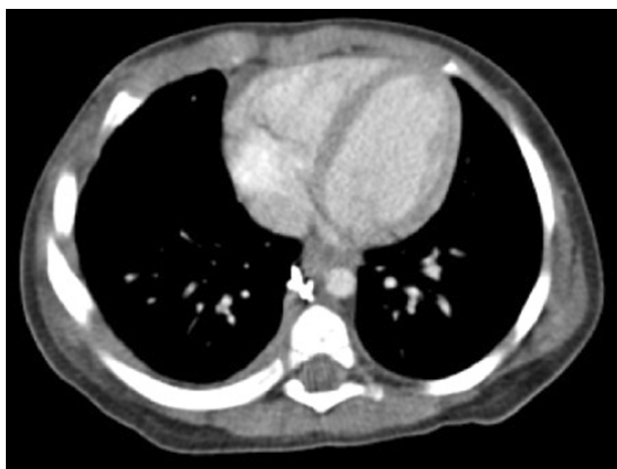

Fig. 5. Follow-up chest CT scan showed resolution of the enhancing lesion.

post-operative hematoma rather than residual tumor because it abutted the surgical clip. However because of the possibility of residual tumor, we treated the patient daily with 25 mg/kg of ibuprofen. Approximately 6 weeks after the operation, follow-up CT scan showed resolution of the enhancing lesion (Fig. 5) and no evidence of recurrent disease until 1 year later.

Discussion

IMT is associated with an inflammatory response that manifests itself by fever. Laboratory evidence of inflammatory response also has been described in patients with IMT. These laboratory findings are hypochromic microcytic anemia, elevated erythrocyte sedimentation rate and elevated thrombocyte counts (600,000 / μ L to 1,000,000 / μ L). Interestingly, as in our case, all above-mentioned laboratory ab-

normalities resolved after tumor excision, and this feature may be useful for diagnosis with recurrent tumour [6].

The standard treatment for IMTs is surgical excision when possible. In most cases, complete surgical excision is effective, with 5-year survival rates of 91%. A significant recurrence rate (25%) exists, probably related to factors precluding complete excision [7].

Adjuvant therapy modalities include radiation therapy, immunomodulatory therapy, and a combination of chemotherapeutic agents in recurrent and metastatic IMT [8]. The efficacy of radiotherapy is controversial. In addition, significant morbidity has been documented [7]. Immunomodulation (cyclosporin-A) and combined chemotherapy has little beneficial effect according to some reports. Complete surgical resection is the appropriate treatment to avoid recurrence as well as unnecessary and potentially harmful therapy. Adjuvant treatment has been tried in patients who underwent incomplete resection because of the high recurrence rate. However some of the patients died of neutropenia, sepsis, renal failure or paraneoplastic syndrome during the adjuvant treatment [6,9]. Even though anaplastic lymphoma kinase (ALK) is negative in our case, the ALK gene, on chromosome 2, is fused to one of several partners such as nonmuscular tropomyosin 3 (TPM3-ALK) which can confer proliferative and metastatic properties to the tumor. Based on these data, crizotinib, a small molecule inhibitor of ALK has shown promising results in patients with ALK+ IMT [10].

IMTs comprise three histological subtypes as followings; one has a vascular pattern consisting of spindle myofibroblasts, the second consists of spindle myofibroblastic cells arranged in fascicular arrays, and the third forms scar-like

patterns with focal plate-like collagen fibers. The first type is richly vascularized, and while surgical resection remains the treatment of choice, this entails much bleeding and involves substantial postoperative morbidity and even mortality [11,12]. Our experience indicates that successful complete resection may be possible with embolization.

To the best of our knowledge, there exist only 3 reports in the literature of IMTs that were completely resected after embolization. Castañón et al. reported the case of an intrathoracic extrapulmonary IMT in a neonate successfully resected after embolization [13]. Similarly, Watanabe et al. described the case of an intracranial inflammatory pseudotumor in a 63-year-old man resected after transcatheter embolization. The tumor was totally resected without much bleeding [14]. Recently Lai et al. have reported a case of IMT in the left nasal cavity of a 13-year-old girl. Preoperative selective embolization of the feeding artery was performed to facilitate surgical excision and to reduce the danger of uncontrolled bleeding [15].

In conclusion, we describe here a rare case of the hypervascular type of mediastinal IMT that could be resected completely following embolization of the feeding vessels. Preoperative embolization is a good option for performing complete resection of hypervascular IMTs, which could reduce the recurrence rate.

References

- Gleason BC, Hornick JL. Inflammatory myofibroblastic tumours: where are we now? *J Clin Pathol* 2008;61:428-37.
- Johnson K, Notrica DM, Carpentieri D, Jaroszewski D, Henry MM. Successful treatment of recurrent pediatric inflammatory myofibroblastic tumor in a single patient with a novel chemotherapeutic regimen containing celecoxib. *J Pediatr Hematol Oncol* 2013;35:414-6.
- Hoover SV, Granston AS, Koch DF, Hudson TR. Plasma cell granuloma of the lung, response to radiation therapy: report of a single case. *Cancer* 1977;39:123-5.
- Lee MH, Lee HB, Lee YC, et al. Bilateral multiple inflammatory myofibroblastic tumors of the lung successfully treated with corticosteroids. *Lung* 2011;189:433-5.
- Diop B, Konate I, Ka S, et al. Mesenteric myofibroblastic tumor: NSAID therapy after incomplete resection. *J Visc Surg* 2011;148:e311-4.
- Karnak I, Senocak ME, Ciftci AO, et al. Inflammatory myofibroblastic tumor in children: diagnosis and treatment. *J Pediatr Surg* 2001;36:908-12.
- Coffin CM, Watterson J, Priest JR, Dehner LP. Extrapulmonary inflammatory myofibroblastic tumor (inflammatory pseudotumor). A clinicopathologic and immunohistochemical study of 84 cases. *Am J Surg Pathol* 1995;19:859-72.
- Meis JM, Enzinger FM. Inflammatory fibrosarcoma of the mesentery and retroperitoneum. A tumor closely simulating inflammatory pseudotumor. *Am J Surg Pathol* 1991;15:1146-56.
- Mehta B, Mascarenhas L, Zhou S, Wang L, Venkatramani R. Inflammatory myofibroblastic tumors in childhood. *Pediatr Hematol Oncol* 2013;30:640-5.
- Butrynski JE, D'Adamo DR, Hornick JL, et al. Crizotinib in ALK-rearranged inflammatory myofibroblastic tumor. *N Engl J Med* 2010;363:1727-33.
- Hammam N, Chbani L, Rami M, et al. A rare tumor of the lung: inflammatory myofibroblastic tumor. *Diagn Pathol* 2012;7:83.
- Zhang Y, Dong ZJ, Zhi XY, Liu L, Hu M. Inflammatory myofibroblastic tumor in lung with osteopulmonary arthropathy. *Chin Med J (Engl)* 2009;122:3094-6.
- Castañón M, Saura L, Weller S, et al. Myofibroblastic tumor causing severe neonatal distress. Successful surgical resection after embolization. *J Pediatr Surg* 2005;40:e9-12.
- Watanabe S, Tosaka M, Miyata T, et al. Intracranial inflammatory pseudotumor resected after transcatheter embolization: a case report. *No Shinkei Geka* 2013;41:987-93.
- Lai V, Wong YC, Lam WY, Tsui WC, Luk SH. Inflammatory myofibroblastic tumor of the nasal cavity. *AJNR Am J Neuroradiol* 2007;28:135-7.