

Brain White Matter Maturation and Early Developmental Outcomes in Preterm Infants With Retinopathy of Prematurity

Seong Joon Ahn,¹ Joo Young Lee,^{2,3} Ji Young Lee,⁴ Young-Jun Lee,⁴ Jong-Min Lee,⁵ Byung Ro Lee,¹ Jinsup Kim,² and Hyun Ju Lee^{2,3}

¹Department of Ophthalmology, Hanyang University Hospital, Hanyang University College of Medicine, Seoul, Republic of Korea

²Department of Pediatrics, Hanyang University Hospital, Hanyang University College of Medicine, Seoul, Republic of Korea

³Division of Neonatology and Developmental Medicine, Hanyang University Hospital, Seoul, Republic of Korea

⁴Department of Radiology, Hanyang University College of Medicine, Seoul, Republic of Korea

⁵Department of Biomedical Engineering, Hanyang University, Seoul, Republic of Korea

Correspondence: Hyun Ju Lee, Department of Pediatrics, Hanyang University Hospital, Hanyang University College of Medicine, 17 Haengdang-dong, Seongdong-gu, Seoul 133-792, Republic of Korea; blesslee77@hanmail.net.

Received: June 14, 2020

Accepted: November 1, 2020

Published: February 1, 2021

Citation: Ahn SJ, Lee JY, Lee JY, et al. Brain white matter maturation and early developmental outcomes in preterm infants with retinopathy of prematurity. *Invest Ophthalmol Vis Sci.* 2021;62(2):2. <https://doi.org/10.1167/iovs.62.2.2>

PURPOSE. To investigate brain white matter pathways using magnetic resonance diffusion tensor imaging (DTI) and correlate the findings with developmental outcomes at 18 months of corrected age in preterm infants with and without retinopathy of prematurity (ROP).

METHODS. In this prospective cohort study, probabilistic maps of the 26 white matter pathways associated with motor, cognitive, visual, and limbic/language functions were generated in 84 preterm infants using DTI obtained at term-equivalent age. The mean fractional anisotropy (FA) and mean diffusivity (MD) values were compared between those with and without ROP. Developmental outcomes were assessed using the third edition of *Bayley Scales of Infant and Toddler Development* (BSID-III) at 18 months of corrected age. Multiple regression analyses were performed to confirm the association among developmental outcomes, white matter pathways, and ROP or severe ROP after adjusting for potential confounders.

RESULTS. The white matter pathways were insignificantly associated with ROP or severe ROP. There were no significant differences in the FA and MD values of the pathways between ROP infants treated with and without bevacizumab therapy. Furthermore, there were no significant differences in BSID-III scores between infants with and without ROP or severe ROP. The BSID-III scores at 18 months of age showed a significant association with FA or MD values in several pathways.

CONCLUSIONS. ROP or severe ROP was insignificantly associated with maturation delay of the white matter pathways. Developmental outcomes were similar between preterm infants with and without ROP or severe ROP or between ROP infants with and without intravitreal bevacizumab therapy.

Keywords: brain white matter, developmental outcome, retinopathy of prematurity

Retinopathy of prematurity (ROP) is a sight-threatening disease observed in preterm neonates. It is characterized by retinal vasoproliferation, which leads to retinal detachment.^{1,2} Despite the advancements in neonatal intensive care, ROP remains one of the leading causes of childhood blindness worldwide.^{1,2} Furthermore, with increased survival of infants with extremely low birth weight, the number of infants at risk for ROP is increasing.

In addition to the sight-threatening disease and associated ocular comorbidities, infants with ROP may experience further developmental problems.³ A magnetic resonance imaging (MRI) study has shown white matter abnormalities in preterm infants and their association with neurodevelopmental disorders such as cerebral palsy and cognitive and psychomotor delay.⁴ Another study has shown an associa-

tion between severe ROP and nonvisual disabilities at the age of 5 years.⁵ However, structural abnormalities in the brain and their association with developmental outcomes have not been extensively studied in infants with ROP, as investigation of neonatal brain development and its alterations is challenging and still under development.

Diffusion tensor imaging (DTI) has been used to evaluate microstructural alterations of the brain in preterm infants.⁶⁻⁸ A few MRI studies have shown brain white matter abnormalities in the infants, including the thalamus and internal capsule.⁹⁻¹¹ Moreover, our previous study analyzing preterm infants with ROP suggests that white matter maturation at term-equivalent ages is more strongly associated with preterm birth than ROP.¹¹ Anatomical landmark structures, including commissural, association, limbic, and projection

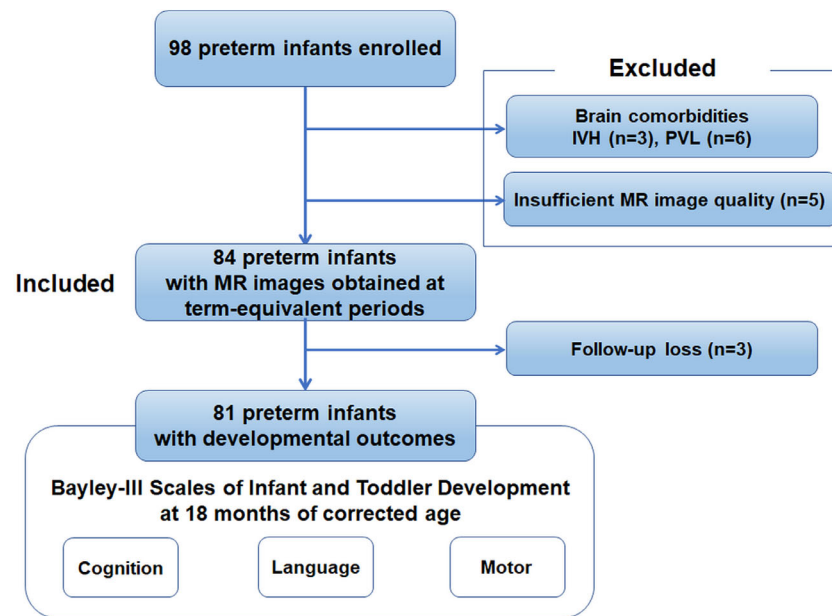


FIGURE 1. A flowchart indicating the inclusion and exclusion criteria of the present study. Eighty-four preterm infants with data on MRI DTI obtained at term-equivalent ages were included, and developmental outcomes regarding cognitive, language, and motor functions were assessed in 81 infants. Both structural findings and developmental outcomes were analyzed in this study.

fibers and deep cortex across the whole brain, were analyzed in this study; however, the results could not be interpreted in terms of developmental functions, as the microstructural alterations could not be functionally correlated in the study. In a previous study, whole-brain DTI analysis based on probabilistic maps of the functional pathways was used to evaluate the association between medical conditions associated with prematurity and alterations of white matter pathways.¹² Using the analyses, the pathways related to motor, cognitive, visual, limbic/language, and somatosensory functions in addition to major white matter tracts could be assessed and correlated functionally with developmental outcomes.¹³

In the present study, we aimed to investigate microstructural alteration of the brain white matter by generating probabilistic maps of white matter pathways with known associated functions in preterm infants. Developmental outcomes at 18 months of corrected age were assessed, and their association with white matter microstructural abnormalities was evaluated. By comparing the microstructural parameters between infants with and without ROP or severe ROP, we investigated the association among brain white matter maturation, early developmental outcomes, and ROP.

METHODS

Participants

A prospective observational cohort of 98 preterm infants (born at a gestational age [GA] of <37 weeks) was recruited from the neonatal intensive care unit of Hanyang University Seoul Hospital between February 2015 and December 2018. MRI DTI imaging was performed in all infants at the near-term age (GA between 36 and 41 weeks). We excluded preterm infants with major congenital malformations or chromosomal anomalies ($n = 0$), those with evidence of intraventricular or intracranial hemorrhage grade > I ($n = 3$) or periventricular leukomalacia ($n = 6$), and those with poor

image quality due to motion artifacts ($n = 5$). In total, 84 preterm infants were included in this study. Figure 1 presents the inclusion and exclusion criteria of the present study and the number of participants meeting these criteria. In 82 of these 84 infants, white matter microstructural abnormalities were assessed in our previous study ($n = 116$) using different regions of interest.¹¹

Prenatal and neonatal data, including maternal information such as maternal age, education (years), sociodemographic factors, GA, GA at the time of MRI scan, birth weight, sex, Apgar scores, and intrauterine growth restriction were prospectively recorded. Neonatal comorbidities were also recorded, including patent ductus arteriosus, sepsis, necrotizing enterocolitis, bronchopulmonary dysplasia, and ROP. The Institutional Review Board of Hanyang University Hospital approved our study protocol, and informed consent for study participation and scanning procedures was obtained from the infants' parents prior to the study. This study was conducted in accordance with the tenets of the Declaration of Helsinki.

ROP Screening and Treatment

According to the current guidelines, all infants with GA of <31 weeks or birth weight of ≤ 1500 g were screened for ROP.^{14–16} Classification of ROP was performed with respect to zone and stage of ROP in accordance with the International Classification of Retinopathy of Prematurity criteria,^{17–20} and maximal ROP stage on sequential examinations was used for our analyses. Severe ROP was defined as a stage ≥ 3 ROP.²¹

The infants with zone I ROP with plus disease or with stage 3 or those with zone II ROP (stage 2 or 3) with plus disease were treated by either intravitreal bevacizumab injection (Avastin, 0.5 mg/0.02 mL; Genentech, San Francisco, CA, USA) or laser photocoagulation.¹⁴ Retinal detachment

surgery such as scleral buckling and vitrectomy was not required in any infant.

Magnetic Resonance Imaging

MRI scans were obtained during natural sleep without sedation at a GA of 36 to 41 weeks in all infants while they were positioned in a blanket and monitored by pulse oximetry during the scan. T1- and T2-weighted MRI scans and DTI scans were obtained using a Philips real-time, compact magnet 3.0-Tesla MRI system (Achieva 3.0T X-Series; Philips Healthcare, Amsterdam, The Netherlands) equipped with a 16-channel SENSE head coil. The T1-weighted images were obtained by sagittal T1 turbo field-echo sequences (repetition time [TR]/echo time [TE], 8.2/3.8 ms), and axial T2-weighted images were obtained using turbo spin-echo sequences (TR/TE, 4800/90 ms). DTI scans were obtained using a single-shot spin-echo planar sequence with a SENSE factor of 2 and an echo-planar imaging factor of 51 (b value, 800 s/mm^2 ; number of diffusion gradient directions, 15; TR/TE, 8100/75 ms; 40–50 axial slices with a 2.0-mm thickness; field of view, 224 mm; matrix size, 112 × 112; total acquisition time, 6.5 minutes).

Image Processing

Diffusion MRI scans were processed using the FMRIB Software Library (<http://www.fmrib.ox.ac.uk/fsl>). A brain mask was created using the Brain Extraction Tool. Motion artifacts and eddy current distortions were corrected based on the rigid registration by normalizing each diffusion-weighted volume to the non-diffusion-weighted volume (b_0) using the FMRIB Linear Image Registration Tool. The tensor model was reconstructed for each voxel using FMRIB Diffusion Toolbox. Subsequently, the scalar metrics, such as fractional anisotropy (FA) and mean diffusivity (MD), were calculated.

To analyze the microstructure in the pathway of interest, we used the probabilistic maps of the fiber pathways on the JHU neonate atlas.²² After we created the pathway atlas by applying a threshold value of 0.1, all FA images were aligned with the JHU neonate FA atlas and warped to the atlas space using advanced normalization tools.^{23,24} The pathway atlas on the JHU neonate atlas was projected onto the individual native FA image using inverse matrices obtained by linear and nonlinear registrations. We used an established probabilistic map of fiber pathways constructed by DTI tractography and measured the average trace values of brain regions with a probability of >10%. The probabilistic map of the white matter tracts was overlaid on the JHU neonate atlas to quantify the FA and MD values of the pathway of interest related to cognitive, motor, and limbic functions, including the genu, body, and splenium of the corpus callosum; cingulum; corticospinal tract; inferior fronto-occipital fasciculus; inferior longitudinal fasciculus; middle cerebellar peduncle; optic radiation; uncinate fasciculus; and auditory radiation. Figure 2 shows a schematic representation of the pathways and MRI scans analyzed in this study, together with the development and functions of the white matter pathways of interest.

Evaluation of Neurodevelopmental Outcomes

At the prematurity-corrected age of 18 months, infants underwent neurological and developmental assessments using the third edition of *Bayley Scales of Infant and Toddler*

Development (BSID-III).²⁵ At the Inclusive Clinic for Developmental Disorders of Hanyang University Hospital, the routine neurological examination was performed by a developmental pediatrician, and the developmental assessment was performed by a pediatric physiotherapist, child psychologist, and neonatologist during the same visit. Developmental outcomes, cognitive, language, and motor BSID-III scores were evaluated based on the child's adjusted age at the time of evaluation. The normative mean for each outcome score was 100, and delayed development was defined as a score of < one SD below the mean (i.e., 85 on the BSID-III scale).²⁶

Statistical Analyses

Continuous variables are represented as mean ± SD. Descriptive statistics were obtained for the demographic data, clinical characteristics, and developmental outcomes. Clinical characteristics were analyzed using the Fisher's exact test or χ^2 test for comparing dichotomous data and Student's t -tests for comparing continuous data. Student's t -tests or Mann-Whitney tests were also used to compare the FA and MD values and developmental outcomes between preterm infants with and without ROP, between those with and without severe ROP, and between ROP infants treated with and without anti-vascular endothelial growth factor (anti-VEGF) therapy. Multiple regression analyses were used to evaluate the association between the microstructural parameters such as FA and MD values and ROP after adjusting for GA at birth, GA at the time of MRI, and other potential confounders. Similar analyses were used to evaluate the association between the parameters and developmental outcomes, adjusted for sex, GA at birth, maternal education, and other clinical confounders. Statistical analyses were performed using SPSS Statistics 23 (IBM Corp., Armonk, NY, USA). $P < 0.05$ was considered statistically significant.

RESULTS

Demographic Data and Clinical Characteristics

Table 1 shows the demographic and clinical characteristics of the preterm infants in subgroups separated based on the presence of ROP. The mean GAs of infants with and without ROP were 26.9 ± 1.7 weeks and 30.3 ± 2.6 weeks, respectively, and the mean birth weights of infants with and without ROP were 964.1 ± 276.3 g and 1387.5 ± 348.2 g, respectively. There were significant differences in several characteristics such as GA, birth weight, length at birth, head circumference, Apgar scores at 1 and 5 minutes, and durations of mechanical ventilation and oxygen therapy between infants with and without ROP (all $P < 0.01$). However, the age at MRI scan, maternal age, and maternal education level were not statistically significant between the groups. Infants with ROP showed significantly higher respiratory distress syndrome, bronchopulmonary dysplasia, and clinical sepsis than those without ROP (all $P < 0.05$). Intravitreal bevacizumab therapy and laser photocoagulation were performed in 11 and four infants, respectively, for the treatment of severe ROP.

Pathway Analysis in Preterm Infants With and Without ROP

Table 2 shows the comparison of FA and MD values in 26 white matter pathways. There were no significant

differences in MD or FA values between infants with and without ROP (all $P > 0.05$). Supplementary Table S1 shows the comparison of DTI parameters between infants with and without severe ROP. FA values were significantly different between infants with and without severe ROP in the body of the corpus callosum ($P = 0.033$), right corticospinal tract ($P = 0.031$), the pathway that connects the V1 (primary visual area)/V2 (secondary visual area) and the V4 in the

left hemisphere ($P = 0.027$) and the right hemisphere ($P = 0.022$), that connecting the V1/V2 and V5/MT ($P = 0.029$), that between the right premotor and primary motor cortices ($P = 0.038$), and that connecting the thalamus and primary somatosensory cortex ($P = 0.037$). However, MD values were not significantly different in any pathway between preterm infants with and without severe ROP. Among the white matter pathways showing statistically significant or

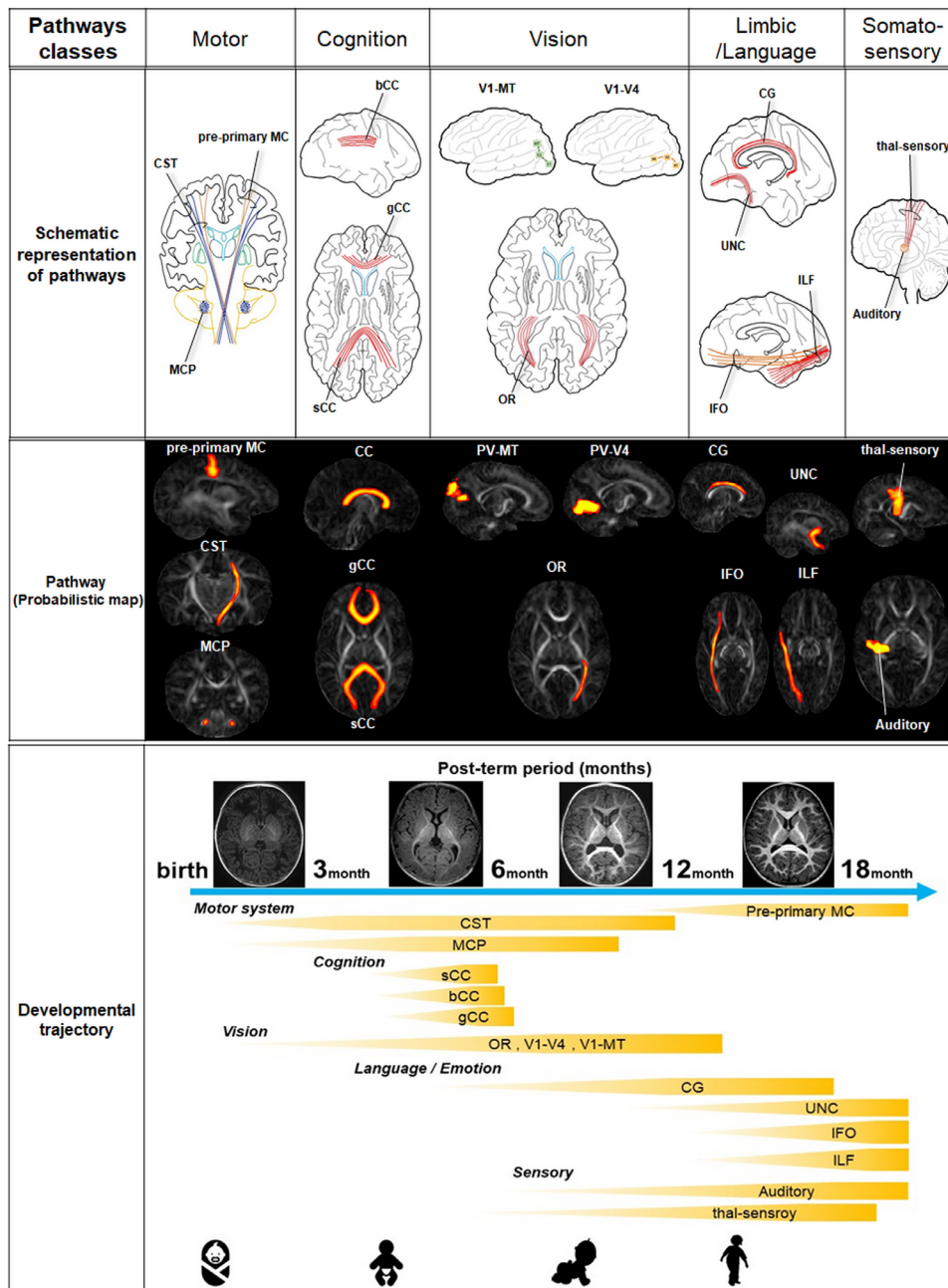


FIGURE 2. Schematic representation of the white matter pathways analyzed in this study (top) and probabilistic maps of the pathways (middle) overlaid on the fractional anisotropy map. Known functions associated with the analyzed white matter pathways together with the post-term period for the development are indicated (bottom). Pre-primary MC, pathway connecting the premotor and primary motor cortices; CST, corticospinal tract; MCP, middle cerebellar peduncle; CC, corpus callosum; gCC, genu of the corpus callosum; sCC, splenium of the corpus callosum; OR, optic radiation; V1, V2, V4, visual cortices; PV-V4, pathway between the V1 (primary visual area)/V2 (secondary visual area) and V4; PV-MT, pathway connecting the V1/V2 and V5/MT (middle temporal visual area); CG, cingulum; UNC, uncinate process; IFO, inferior fronto-occipital fasciculus; ILF, inferior longitudinal fasciculus; thal-sensory, pathway between the sensory thalamus and primary somatosensory cortex; auditory, auditory radiation.

TABLE 1. Comparison of Clinical Characteristics in Preterm Neonates With and Without ROP

Parameters	Preterm Neonates		P*
	Without ROP (n = 44)	With ROP (n = 40)	
Gestational age (wk), mean ± SD	30.3 ± 2.6	26.9 ± 1.7	<0.001
Male:female, n	17:27	18:22	0.555
Birth weight (g), mean ± SD	1387.5 ± 348.2	964.1 ± 276.3	<0.001
Age at MRI scan (wk), mean ± SD	36.7 ± 1.5	37.0 ± 1.8	0.354
Maternal age (y), mean ± SD	34.0 ± 4.0	34.4 ± 4.6	0.688
Maternal education, n			0.521
High school	8	4	
College	33	32	
Graduate school	3	4	
Length at birth (cm), mean ± SD	40.0 ± 4.0	35.0 ± 4.5	<0.001
Head circumference (cm), mean ± SD	28.2 ± 2.6	25.1 ± 2.3	<0.001
Apgar score, mean ± SD			
At 1 min	3.8 ± 1.6	2.9 ± 1.7	0.009
At 5 min	6.6 ± 1.1	5.9 ± 1.3	0.004
Mechanical ventilation (d), mean ± SD	8.5 ± 7.9	27.8 ± 28.2	<0.001
O ₂ therapy (d), mean ± SD	21.5 ± 21.8	49.2 ± 28.9	<0.001
Intrauterine growth retardation, n	11	9	0.788
In vitro fertilization, n	9	13	0.210
Gestational diabetes mellitus, n	3	2	1.0
Pregnancy-induced hypertension, n	4	8	0.215
Premature rupture of membrane, n	16	15	1.0
Placenta previa, n	0	2	0.224
Cesarean section, n	34	33	0.551
Respiratory distress syndrome, n	25	36	0.021
Bronchopulmonary dysplasia, n	16	33	<0.001
Necrotizing colitis, n	7	8	0.625
Intraventricular hemorrhage, grade 1, n	6	12	0.068
Clinical sepsis, n	17	28	0.004

Boldface indicates statistical significance.

*For categorical variables, Fisher's exact or χ^2 test was used for comparisons between the groups. For continuous variables, unpaired *t*-tests were used for comparisons between the groups.

TABLE 2. Comparison of FA and MD Values Between Preterm Infants With and Without ROP

Pathways	FA, Mean ± SD			MD, Mean ± SD		
	Without ROP (n = 44)	With ROP (n = 40)	P	Without ROP (n = 44)	With ROP (n = 40)	P
Corpus callosum						
Genu	0.171 ± 0.026	0.174 ± 0.029	0.640	0.00152 ± 0.000125	0.00148 ± 0.000127	0.188
Body	0.191 ± 0.029	0.196 ± 0.035	0.492	0.00156 ± 0.000124	0.00152 ± 0.000140	0.177
Splenuum	0.168 ± 0.025	0.167 ± 0.031	0.907	0.00152 ± 0.000144	0.00149 ± 0.000146	0.281
Cingulum, left	0.161 ± 0.019	0.163 ± 0.026	0.694	0.00131 ± 0.000095	0.00128 ± 0.000093	0.075
Cingulum, right	0.155 ± 0.019	0.156 ± 0.024	0.814	0.00131 ± 0.000092	0.00127 ± 0.000105	0.057
Corticospinal tract, left	0.259 ± 0.038	0.272 ± 0.042	0.141	0.00134 ± 0.000136	0.00130 ± 0.000116	0.208
Corticospinal tract, right	0.258 ± 0.034	0.270 ± 0.038	0.125	0.00146 ± 0.000155	0.00141 ± 0.000114	0.121
Inferior fronto-occipital fasciculus, left	0.178 ± 0.030	0.181 ± 0.036	0.612	0.00147 ± 0.000133	0.00144 ± 0.000143	0.398
Inferior fronto-occipital fasciculus, right	0.173 ± 0.028	0.176 ± 0.034	0.658	0.00145 ± 0.000128	0.00143 ± 0.000150	0.586
Inferior longitudinal fasciculus, left	0.173 ± 0.024	0.176 ± 0.029	0.598	0.00153 ± 0.000140	0.00150 ± 0.000146	0.406
Inferior longitudinal fasciculus, right	0.171 ± 0.021	0.174 ± 0.027	0.567	0.00143 ± 0.000116	0.00141 ± 0.000135	0.442
Middle cerebellar peduncle	0.204 ± 0.031	0.210 ± 0.040	0.459	0.00159 ± 0.000224	0.00153 ± 0.000186	0.185
Optic radiation, left	0.227 ± 0.034	0.235 ± 0.042	0.326	0.00146 ± 0.000126	0.00144 ± 0.000130	0.556
Optic radiation, right	0.220 ± 0.035	0.226 ± 0.040	0.424	0.00145 ± 0.000124	0.00143 ± 0.000150	0.621
Uncinate fasciculus, left	0.168 ± 0.027	0.172 ± 0.029	0.505	0.00146 ± 0.000163	0.00142 ± 0.000139	0.260
Uncinate fasciculus, right	0.172 ± 0.025	0.177 ± 0.029	0.426	0.00141 ± 0.000134	0.00136 ± 0.000127	0.144
PV-V4, left	0.147 ± 0.017	0.145 ± 0.022	0.612	0.00141 ± 0.000127	0.00139 ± 0.000173	0.544
PV-V4, right	0.150 ± 0.017	0.149 ± 0.023	0.755	0.00139 ± 0.000118	0.00137 ± 0.000149	0.579
PV-MT, left	0.149 ± 0.025	0.147 ± 0.025	0.743	0.00154 ± 0.000153	0.00149 ± 0.000147	0.206
PV-MT, right	0.157 ± 0.020	0.155 ± 0.026	0.828	0.00143 ± 0.000130	0.00141 ± 0.000128	0.509
Pre-primary MC, left	0.152 ± 0.022	0.157 ± 0.024	0.381	0.00134 ± 0.000125	0.00131 ± 0.000117	0.302
Pre-primary MC, right	0.152 ± 0.021	0.158 ± 0.025	0.201	0.00137 ± 0.000121	0.00133 ± 0.000102	0.084
Thalamus-primary somatosensory cortex, left	0.185 ± 0.023	0.192 ± 0.026	0.249	0.00134 ± 0.000108	0.00131 ± 0.000095	0.327
Thalamus-primary somatosensory cortex, right	0.196 ± 0.024	0.203 ± 0.030	0.248	0.00133 ± 0.000099	0.00131 ± 0.000104	0.369
Auditory radiation, left	0.208 ± 0.025	0.213 ± 0.029	0.397	0.00128 ± 0.000096	0.00126 ± 0.000084	0.486
Auditory radiation, right	0.207 ± 0.021	0.212 ± 0.028	0.352	0.00124 ± 0.000079	0.00122 ± 0.000080	0.224

PV-V4, pathway between the V1 (primary visual area)/V2 (secondary visual area) and V4; PV-MT, pathway connecting the V1/V2 and V5/MT (middle temporal visual area).

TABLE 3. Comparison of Developmental Outcomes and Frequency of Developmental Delay Between Infants With and Without ROP and Between Those With and Without Severe ROP

Category	ROP			Severe ROP		
	Without (<i>n</i> = 42)	With (<i>n</i> = 39)	<i>P</i> [*]	Without (<i>n</i> = 65)	With ROP (<i>n</i> = 16)	<i>P</i> [†]
Cognitive scores	98.0 ± 14.7	92.3 ± 13.9	0.074	96.5 ± 14.3	90.2 ± 14.5	0.118
Cognitive delay, %	11.9	23.1	0.184	16.9	18.8	1.0
Language scores	91.1 ± 14.4	87.3 ± 15.2	0.258	89.5 ± 14.1	88.5 ± 17.9	0.817
Language delay, %	38.1	43.6	0.615	41.5	37.5	0.768
Motor scores	97.5 ± 17.3	91.4 ± 17.6	0.120	95.4 ± 17.8	90.9 ± 16.8	0.367
Motor delay, %	19.0	23.1	0.656	21.5	18.8	1.0

^{*} Student's *t*-test or χ^2 test.

[†] Mann-Whitney *U* test or Fisher's exact test.

marginally significant differences ($P < 0.1$) in FA or MD values between those with and without ROP or between those with severe ROP and the others, the parameters did not show a statistically significant association with ROP or severe ROP after adjusting for potential confounders such as GA, GA at MRI scan, bronchopulmonary dysplasia (BPD), and sepsis.

Early Developmental Outcomes and Their Associations with Retinopathy of Prematurity

Among the 84 infants included in this study, developmental outcomes of cognitive, motor, and language functions were evaluated in 81 infants. Table 3 presents the comparison of BSID-III scores between preterm infants with and without ROP and between those with and without severe ROP. There were marginally significant differences in the mean cognitive score between infants with and without ROP ($P = 0.074$ by Student's *t*-test); however, there were no significant differences in the mean language score ($P = 0.258$) or motor score ($P = 0.120$) between the two groups. Between infants with and without severe ROP, there were no statistically significant differences in the three developmental scores (all $P > 0.05$ by Mann-Whitney test). There were no significant differences in the frequencies of developmental delay in the three functions between infants with and without ROP and between those with and without severe ROP (all $P > 0.05$). After adjusting for sex, GA, and maternal education, no developmental outcomes showed a significant association with ROP or severe ROP (all $P > 0.05$).

Association Between Multiple White Matter Pathways and Developmental Outcomes

Using multiple regression analyses, associations between FA or MD values of the white matter pathways and BSID-III scores were assessed. Supplementary Table S2 presents the

white matter pathways significantly associated with each category of BSID-III assessment in univariate and multivariate analyses. In multivariate analyses including sex, GA, GA at MRI scan, BPD, sepsis, and mother education, cognitive scores showed a significant association with FA values of the left corticospinal tract (regression coefficient [r] = 87.5, $P = 0.046$) and middle cerebellar peduncle ($r = 115.4$, $P = 0.017$) and MD values of the left ($r = -36.1$, $P = 0.008$) and right ($r = -36.7$, $P = 0.003$) corticospinal tract, middle cerebellar peduncle ($r = -28.4$, $P = 0.001$), left uncinate fasciculus ($r = -29.4$, $P = 0.012$), left pathway between the premotor and primary motor cortices ($r = -30.3$, $P = 0.035$), and left ($r = -43.6$, $P = 0.027$) and right ($r = -45.2$, $P = 0.040$) auditory radiation. Using the same analyses, language and motor scores were significantly associated with the FA values of the middle cerebellar peduncle ($r = 133.6$, $P = 0.007$; $r = 148.8$, $P = 0.013$, respectively).

Association of Intravitreal Bevacizumab Therapy with Brain Microstructure or Developmental Outcomes

The Bayley scores were compared between ROP infants treated with and without intravitreal bevacizumab therapy, as presented in Table 4. Between the two groups, there were no significant differences in the developmental scores (all $P > 0.05$). Additionally, there were no significant differences in the frequencies of developmental delay in cognitive, motor, or language functions between ROP infants treated with and without intravitreal bevacizumab therapy ($P > 0.05$). There were significant associations between intravitreal bevacizumab therapy and MD values of the pathway between the premotor and primary motor cortices ($r = 0.108$, $P = 0.023$ in the left hemisphere; $r = 0.096$, $P = 0.025$ in the right hemisphere) in multiple regression analyses including clinical variables such as GA, GA at MRI scan, BPD, and sepsis.

TABLE 4. Comparison of Developmental Outcomes and Frequency of Developmental Delay Between Infants With ROP Treated with Anti-VEGF Therapy and Other Infants with ROP

Category	ROP Without Anti-VEGF Treatment (<i>n</i> = 29)	ROP With Anti-VEGF Treatment (<i>n</i> = 10)	<i>P</i>
Cognitive scores	93.8 ± 12.7	87.8 ± 16.8	0.241
Cognitive delay, <i>n</i> (%)	6 (20.7)	3 (30)	0.669
Language scores	87.6 ± 14.2	86.5 ± 18.5	0.844
Language delay, <i>n</i> (%)	13 (44.8)	4 (40)	1.0
Motor scores	90.9 ± 17.0	92.7 ± 20.0	0.784
Motor delay, <i>n</i> (%)	8 (27.6)	1 (10)	0.400

DISCUSSION

In this study, we used probabilistic maps of the white matter pathways and BSID-III scores to evaluate white matter maturation and developmental outcomes in infants with and without ROP. By comparing white matter microstructural integrity and developmental outcomes between preterm infants with and without ROP or severe ROP, this study identified several pathways that were significantly different between infants with and without severe ROP. However, multivariate analyses showed that ROP or severe ROP was not independently associated with white matter maturation or early developmental outcomes.

Our previous study showed that preterm birth as compared with ROP may be more strongly associated with white matter maturation at term-equivalent ages; however, severe ROP may be associated with decreased structural connectivity.¹¹ This is not contradictory to the present findings, because the areas of interest for DTI analyses were different between the studies; however, in our previous study covering extensive areas including anatomic landmarks of the brain, the results could not be functionally correlated, as the region of interest was anatomically determined and functional outcomes such as cognition and motor had not been evaluated in the study. In contrast, the present study evaluated pathways of interest, based on functional considerations, which have associated neurodevelopmental functions. Our selection of pathways with known associated functions, in accordance with a previous method by Akazawa et al.,¹² covers language, motor, and cognitive functions; thus, we could correlate microstructural development of functional pathways with neurodevelopmental outcomes on BSID-III scores.

Several studies reported an association between ROP and delayed maturation of the white matter tracts using DTI analyses.^{10,11,21} Thompson et al.²¹ showed microscopic alterations of optic radiations in preterm infants with severe ROP. Our previous study also demonstrated that several white matter tracts are significantly different between infants with ROP and controls.¹¹ However, as ROP is usually associated with multiple comorbidities such as extreme prematurity and sepsis, the confounding effects of these comorbidities should be excluded to elucidate the true association between ROP and maturation delay of the white matter. Multivariate analyses including several confounders such as GA and sepsis showed that only a few of the several areas showing significant differences between infants with ROP and full-term controls were significantly associated with ROP or severe ROP,¹¹ supporting the importance of controlling the effects of potential confounders in determining the true association between ROP and main outcomes—brain microstructural parameters and developmental outcomes. In the present study, significant differences in several pathways, including the pathway between the thalamus and primary somatosensory cortex, were observed by comparing the FA and MD values between infants with and without severe ROP. However, multivariate analyses showed no significant association between the parameters of the white matter pathways and ROP or severe ROP.

In addition to the structural assessment of a number of white matter pathways involving multiple functions of the brain at term-equivalent ages, functional/developmental outcomes were evaluated in this longitudinal study. In our study, multiple white matter pathways were associated with developmental outcomes—cognitive, language, and motor

functions. Although cognitive function was associated with several white matter pathways, language or motor function was associated with only one pathway of interest (Supplementary Table S2). As cognitive function is a group of functions including memory, general intelligence, learning, orientation, perception, and attention, our results indicate the involvement of multiple white matter pathways in childhood cognitive function and its development. Our results showed a significant association between the middle cerebellar peduncle and early developmental outcomes in cognitive, language, and motor functions in preterm infants. Several studies have suggested the role of the cerebellum in higher-order cognitive functions.^{27–29} Fibers projecting to and from the cerebellum, such as the superior and middle cerebellar peduncle, may be involved in the functions. Furthermore, previous studies have suggested cerebellar contributions to language and motor functions^{30,31} and reduced cerebellar volumes and impaired developmental outcomes in infants with ROP.³² Therefore, the cerebellum needs to be carefully assessed in preterm infants with or without ROP who present with cognitive, language, or motor dysfunction.

None of the vision-associated white matter pathways assessed in this study, however, showed any significant association with ROP or developmental outcomes. Because retinopathy in all of our patients with ROP was successfully treated or regressed, the abnormal development associated with visual deprivation due to ROP in related white matter pathways such as optic radiation and pathways connecting visual areas might not occur, leading to structural and functional maturation similar to that in preterm infants without ROP. However, because it is unclear whether visual deprivation associated with untreated or unsuccessfully treated severe ROP leads to maturational delay of the vision-associated white matter pathways, further studies are needed to validate the association.

Anti-VEGF is currently being used for the treatment of severe ROP, because the Bevacizumab Eliminates the Angiogenic Threat for Retinopathy of Prematurity (BEAT-ROP) study showed promising effects of intravitreal bevacizumab therapy for the regression of ROP.³³ However, long-term systemic safety of anti-VEGF therapy has not been fully elucidated. As VEGF is also critical for brain development, blocking its effects by intravitreal bevacizumab injection may result in unanticipated consequences, such as maturational delay of the brain, as injected bevacizumab may enter the systemic circulation and suppress brain growth. Our study showed a significant association between the MD parameters of the pathway between the premotor and primary motor cortex and anti-VEGF therapy, which is consistent with the findings of a previous study by Lien et al.³⁴ on psychomotor defects in the intravitreal bevacizumab therapy plus laser group compared to the laser group. Another study has shown lower motor scores and higher rates of severe neurodevelopmental disability at 18 months of corrected age in the infants treated with intravitreal bevacizumab therapy.³⁵ However, our previous and present studies did not show any significant differences in white matter maturation and developmental outcomes between the ROP infants treated with and without the therapy. Greater GA at birth (26.8 weeks in our study vs. 24.9 weeks in the study by Morin et al.³⁵) and the difference in the control group (ROP infants treated without anti-VEGF therapy versus ROP infants treated with laser therapy) might cause such discrepancies between the studies. Nevertheless, future studies

that include a larger number of infants with ROP, particularly those treated with intravitreal anti-VEGF injections, are required to draw a conclusion on the effect of anti-VEGF therapy on brain maturation and neurodevelopmental outcomes.

The present study has several limitations requiring careful interpretations. First, our study used MRI scans obtained at the term-equivalent period to assess white matter maturation at baseline. Scans obtained at 18 months of corrected age may also be useful to correlate functionally with early developmental outcomes, as the scans provide information on structural maturation at the time of developmental assessment. However, performing MRI DTI successfully in 18-month-old infants would be significantly difficult without pharmacologic sedation, which may pose medical risks to the infants. Furthermore, a longer follow-up period may be needed to draw conclusions on the relationship between ROP and developmental outcomes. Particularly, assessment of language function at 18 months of GA requires careful interpretation because of the limited accuracy of the evaluation at such an early period. Moreover, the number of white matter pathways analyzed in this study was also limited. Furthermore, visual acuities were not evaluated in our infants, as visual function at 18 months of corrected age could not be assessed reliably with quantitative scales in most cases; we believe that a longer follow-up may be required for correlating structural findings with visual functions, which might be assessed reliably at subsequent follow-up visits. Finally, brain development in children can change at any age; thus, white matter microstructure and its correlation with neurodevelopmental function can be dynamic over time in children. Therefore, the structural alterations at near-term ages and functional outcomes at 18 months of corrected age can change significantly later, which also necessitates future investigation.

In conclusion, ROP or severe ROP was insignificantly associated with the 26 pathways with cognitive, motor, visual, and limbic functions. Developmental outcomes were similar between preterm infants with and without ROP or severe ROP and also between ROP infants with and without anti-VEGF therapy. Although future studies should investigate long-term developmental outcomes and white matter maturation in infants treated with anti-VEGF therapy for ROP, our study suggests a potential association between the therapy and maturation of the motor-associated white matter pathways.

Acknowledgments

Supported by a National Research Foundation of Korea Grant funded by the Korean Government Ministry of Science and ICT (NRF-2021M3E5D1A01015175) and by the National Research Foundation of Korea Grant funded by the Korean Government MIST (NRF-2020-R1F1A1048529 and 2020-M3E5D9080787).

Disclosure: **S.J. Ahn**, None; **J.Y. Lee**, None; **J.Y. Lee**, None; **Y.-J. Lee**, None; **J.-M. Lee**, None; **B.R. Lee**, None; **J. Kim**, None; **H.J. Lee**, None

References

- Hartnett ME, Penn JS. Mechanisms and management of retinopathy of prematurity. *N Engl J Med*. 2012;367(26):2515–2526.
- Hellström A, Smith LE, Dammann O. Retinopathy of prematurity. *Lancet*. 2013;382(9902):1445–1457.
- Msall ME, Phelps DL, DiGaudio KM, et al. Severity of neonatal retinopathy of prematurity is predictive of neurodevelopmental functional outcome at age 5.5 years. Behalf of the Cryotherapy for Retinopathy of Prematurity Cooperative Group. *Pediatrics*. 2000;106(5):998–1005.
- Woodward LJ, Anderson PJ, Austin NC, Howard K, Inder TE. Neonatal MRI to predict neurodevelopmental outcomes in preterm infants. *N Engl J Med*. 2006;355(7):685–694.
- Schmidt B, Davis PG, Asztalos EV, Solimano A, Roberts RS. Association between severe retinopathy of prematurity and nonvisual disabilities at age 5 years. *JAMA*. 2014;311(5):523–525.
- Anjari M, Srinivasan L, Allsop JM, et al. Diffusion tensor imaging with tract-based spatial statistics reveals local white matter abnormalities in preterm infants. *NeuroImage*. 2007;35(3):1021–1027.
- Bassi L, Chew A, Merchant N, et al. Diffusion tensor imaging in preterm infants with punctate white matter lesions. *Pediatr Res*. 2011;69(6):561–566.
- Alexander AL, Lee JE, Lazar M, Field AS. Diffusion tensor imaging of the brain. *Neurotherapeutics*. 2007;4(3):316–329.
- Kim DY, Park HK, Kim NS, Hwang SJ, Lee HJ. Neonatal diffusion tensor brain imaging predicts later motor outcome in preterm neonates with white matter abnormalities. *Ital J Pediatr*. 2016;42(1):104.
- Rose J, Vassar R, Cahill-Rowley K, et al. Neonatal physiological correlates of near-term brain development on MRI and DTI in very-low-birth-weight preterm infants. *NeuroImage Clin*. 2014;5:169–177.
- Ahn SJ, Park HK, Lee BR, Lee HJ. Diffusion tensor imaging analysis of white matter microstructural integrity in infants with retinopathy of prematurity. *Invest Ophthalmol Vis Sci*. 2019;60(8):3024–3033.
- Akazawa K, Chang L, Yamakawa R, et al. Probabilistic maps of the white matter tracts with known associated functions on the neonatal brain atlas: application to evaluate longitudinal developmental trajectories in term-born and preterm-born infants. *NeuroImage*. 2016;128:167–179.
- Chau V, Synnes A, Grunau RE, Poskitt KJ, Brant R, Miller SP. Abnormal brain maturation in preterm neonates associated with adverse developmental outcomes. *Neurology*. 2013;81(24):2082–2089.
- Fierson WM, American Academy of Pediatrics Section on Ophthalmology, American Academy of Ophthalmology, American Association for Pediatric Ophthalmology and Strabismus, American Association of Certified Orthoptists. Screening examination of premature infants for retinopathy of prematurity. *Pediatrics*. 2013;131(1):189–195.
- Section on Ophthalmology American Academy of Pediatrics, American Academy of Ophthalmology, American Association for Pediatric Ophthalmology and Strabismus. Screening examination of premature infants for retinopathy of prematurity. *Pediatrics*. 2006;117(2):572–576.
- Screening Examination of Premature Infants for Retinopathy of Prematurity. A joint statement of the American Academy of Pediatrics, the American Association for Pediatric Ophthalmology and Strabismus, and the American Academy of Ophthalmology. *Ophthalmology*. 1997;104(5):888–889.
- International Committee for the Classification of Retinopathy of Prematurity. The International Classification of Retinopathy of Prematurity revisited. *Arch Ophthalmol*. 2005;123(7):991–999.
- An international classification of retinopathy of prematurity. II. The classification of retinal detachment. The International Committee for the Classification of the Late

- Stages of Retinopathy of Prematurity. *Arch Ophthalmol*. 1987;105(7):906–912.
19. An international classification of retinopathy of prematurity. The Committee for the Classification of Retinopathy of Prematurity. *Arch Ophthalmol*. 1984;102(8):1130–1134.
 20. An international classification of retinopathy of prematurity. *Pediatrics*. 1984;74(1):127–133.
 21. Thompson DK, Thai D, Kelly CE, et al. Alterations in the optic radiations of very preterm children-perinatal predictors and relationships with visual outcomes. *NeuroImage Clin*. 2013;4:145–153.
 22. Oishi K, Mori S, Donohue PK, et al. Multi-contrast human neonatal brain atlas: application to normal neonate development analysis. *NeuroImage*. 2011;56(1):8–20.
 23. Avants BB, Tustison NJ, Song G, Cook PA, Klein A, Gee JC. A reproducible evaluation of ANTs similarity metric performance in brain image registration. *NeuroImage*. 2011;54(3):2033–2044.
 24. Avants BB, Epstein CL, Grossman M, Gee JC. Symmetric diffeomorphic image registration with cross-correlation: evaluating automated labeling of elderly and neurodegenerative brain. *Med Image Anal*. 2008;12(1):26–41.
 25. Bayley N. *Bayley Scales of Infant and Toddler Development*. 3rd ed. San Antonio, TX: Harcourt Assessment; 2006.
 26. Johnson S, Moore T, Marlow N. Using the Bayley-III to assess neurodevelopmental delay: which cut-off should be used? *Pediatr Res*. 2014;75(5):670–674.
 27. Schmahmann JD. An emerging concept. The cerebellar contribution to higher function. *Arch Neurol*. 1991;48(11):1178–1187.
 28. Koziol LF, Budding D, Andreasen N, et al. Consensus paper: the cerebellum's role in movement and cognition. *Cerebellum*. 2014;13(1):151–177.
 29. Stoodley CJ. The cerebellum and cognition: evidence from functional imaging studies. *Cerebellum*. 2012;11(2):352–365.
 30. Kuper M, Dimitrova A, Thurling M, et al. Evidence for a motor and a non-motor domain in the human dentate nucleus—an fMRI study. *NeuroImage*. 2011;54(4):2612–2622.
 31. Leiner HC, Leiner AL, Dow RS. Cognitive and language functions of the human cerebellum. *Trends Neurosci*. 1993;16(11):444–447.
 32. Sveinsdottir K, Ley D, Hovel H, et al. Relation of retinopathy of prematurity to brain volumes at term equivalent age and developmental outcome at 2 years of corrected age in very preterm infants. *Neonatology*. 2018;114(1):46–52.
 33. Mintz-Hittner HA, Kennedy KA, Chuang AZ, BEAT-ROP Cooperative Group. Efficacy of intravitreal bevacizumab for stage 3+ retinopathy of prematurity. *N Engl J Med*. 2011;364(7):603–615.
 34. Lien R, Yu MH, Hsu KH, et al. Neurodevelopmental outcomes in infants with retinopathy of prematurity and bevacizumab treatment. *PLoS One*. 2016;11(1):e0148019.
 35. Morin J, Luu TM, Superstein R, et al. Neurodevelopmental outcomes following bevacizumab injections for retinopathy of prematurity. *Pediatrics*. 2016;137(4):e20153218.