

## Research Article

# Effect of Hemodialysis on Anterior Chamber Angle Measured by Anterior Segment Optical Coherence Tomography

Yong Un Shin <sup>1</sup>, Ji Hong Kim <sup>1</sup>, Heeyoon Cho <sup>1</sup>, Dae Sung Kim <sup>1</sup>, Joo-Hark Yi <sup>2</sup>, Sang-Woong Han <sup>2</sup> and Mincheol Seong <sup>1</sup>

<sup>1</sup>Department of Ophthalmology, Hanyang University College of Medicine, Seoul, Republic of Korea

<sup>2</sup>Division of Nephrology, Department of Internal Medicine, Hanyang University College of Medicine, Seoul, Republic of Korea

Correspondence should be addressed to Sang-Woong Han; [cardion@hanyang.ac.kr](mailto:cardion@hanyang.ac.kr) and Mincheol Seong; [goddns76@hanmail.net](mailto:goddns76@hanmail.net)

Received 11 October 2018; Revised 9 December 2018; Accepted 21 January 2019; Published 14 August 2019

Academic Editor: Anna Nowinska

Copyright © 2019 Yong Un Shin et al. This is an open access article distributed under the Creative Commons Attribution License, which permits unrestricted use, distribution, and reproduction in any medium, provided the original work is properly cited.

**Purpose.** To investigate the effect of hemodialysis (HD) on the anterior chamber angle by anterior segment optical coherence tomography (ASOCT) and other ophthalmologic parameters in patients with end-stage kidney disease (ESKD). **Methods.** A prospective observational study was performed on 20 patients who underwent HD for ESKD. Anterior chamber angle images were obtained by 16 mm line scan of ASOCT. The angle opening distance (AOD) and the trabecular-iris space area (TISA) were determined using the ImageJ program. Additional 12 mm horizontal and 9 mm vertical wide-field scans centered on the posterior pole were performed for the measurement of peripapillary retinal nerve fiber layer (pRNFL) thickness and macular ganglion cell-inner plexiform layer (mGCIPL) thickness. Changes in intraocular pressure (IOP), AOD, TISA, pRNFL thickness, and mGCIPL thickness before and after HD were statistically analyzed. **Results.** The IOP decreased significantly from  $17.5 \pm 3.4$  before HD to  $16.2 \pm 2.3$  after HD ( $P = 0.017$ ). There was a statistically significant decrease in AOD 750 and TISA 750 ( $P = 0.005$  and  $P = 0.007$ , respectively). AOD 500 and TISA 500 also decreased, which was almost statistically significant ( $P = 0.061$  and  $P = 0.081$ , respectively). Mean pRNFL thickness and mGCIPL thickness did not show significant change after HD. **Conclusion.** We observed a significant decrease in IOP and anterior chamber angle measurements after HD. Our study suggests that HD can influence the anterior segment structure of eyes.

## 1. Introduction

Chronic kidney disease is a condition that occurs due to a permanent reduction in glomerular filtration rate and irreversible renal dysfunction. End-stage kidney disease (ESKD) is defined as a glomerular filtration rate less than  $15 \text{ ml/min/1.73 m}^2$  and requires renal replacement therapy, such as dialysis or renal transplantation. Hemodialysis (HD) is a common renal replacement therapy, which removes excessive fluid and uremic substances, thereby balancing the volume composition of the body fluids.

Dynamic changes in body fluid composition due to HD result in systemic changes, such as decreases in body weight and systolic blood pressure [1, 2]. In addition to these systemic changes, HD has been reported to exhibit various effects on the eye, such as refractive changes, dry eye,

conjunctival calcium deposits, band keratopathy, lenticular opacities, and changes in intraocular pressure (IOP) [3–6]. Recently, there have been several reports on changes in retinal and choroidal thickness before and after HD using optical coherence tomography [7–10].

Hemodynamic changes due to HD may affect the composition of aqueous humor, which may influence the structure of the anterior chamber angle. However, the effect of HD on the anterior chamber angle has not been reported. In addition, few reports have examined the changes in peripapillary retinal nerve fiber layer (pRNFL) and macular ganglion cell-inner plexiform layer (mGCIPL) after HD.

In this study, we investigated the effect of HD on the anterior chamber angle in patients with ESKD undergoing HD through anterior segment optical coherence tomography

(ASOCT). Furthermore, we also investigated the changes in pRNFL and mGCIPL thickness after HD by swept-source optical coherence tomography.

## 2. Methods

**2.1. Patients.** Our study protocol complied with the Declaration of Helsinki and was approved by the Institutional Review Board (IRB) of Hanyang University Guri Hospital. A prospective observational study of ESKD patients undergoing HD at Hanyang University Guri Hospital was performed (IRB no. 2016-05-005). We recruited patients who were regularly dialyzed in our dialysis room to participate in the study. All patients underwent baseline measurement of body weight and blood pressure before and after HD. After detailed explanation of the study, informed consent was obtained from all participants.

Exclusion criteria were as follows: (1) previous history of intraocular surgery or glaucoma diagnosis, (2) baseline IOP greater than 22 mmHg, (3) presence of glaucomatous optic disc changes including excavation, thinning, or notching of the neuroretinal rim, (4) closed or occludable angle in gonioscopic examination, (5) axial length greater than 26 mm, (6) combined anterior segment disease such as corneal opacity, and (7) combined macular and retinal diseases such as central serous chorioretinopathy and age-related macular degeneration, except diabetic retinopathy.

**2.2. Ocular Examinations.** The right eye was selected for ophthalmic examination to shorten the interval between HD and examinations. All ophthalmologic examinations were performed in the dialysis room to exclude spurious effects. To do so, all ophthalmic devices were placed at the entrance of the dialysis room. In particular, the OCT was installed in a separately shaded area, minimizing changes in pupil size due to illumination. At the beginning of HD, all patients underwent comprehensive ophthalmic examinations including best-corrected visual acuities, slit-lamp examinations, gonioscopy, IOP, anterior chamber depth (ACD), axial length (AL), and indirect ophthalmoscopy. IOP was measured three times in succession using a TonoPen® (Reichert Inc., Depew, NY, USA), and the mean value of measurements was used for the study. ACD and AL were measured using an IOL master® (Carl Zeiss, Jena, Germany).

OCT was performed by swept-source optical coherence tomography (DRI-OCT Triton®, Topcon Inc., Tokyo, Japan). The device can be extended to include anterior imaging. To obtain images of the same area before and after HD, the patient's nasal and temporal limbus were marked with a marking pen. After positioning the anterior segment attachment on the OCT device, anterior chamber angle images were obtained by performing a 16 mm line scan to include the two points marked. In addition, posterior pole imaging was performed to obtain pRNFL thickness and mGCIPL thickness. Using a 1,050 nm wavelength light

source, the device provides wide-field three-dimensional macular volume scanning protocols, covering a 12 mm × 9 mm area on the posterior pole, including the macular and peripapillary areas. After HD, systemic parameters such as body weight and blood pressure and ophthalmic parameters such as IOP, ACD, AL, and OCT measurements were measured again. The interval between ophthalmologic examinations and HD was less than 10 minutes.

**2.3. Analysis of OCT Measurements.** The images obtained through ASOCT were exported and saved as Tiff files via OCT viewer software. We loaded the exported image into the ImageJ program (software version 1.46; National Institutes of Health, Bethesda, MD, USA). Postprocessing of images was performed to clearly identify the structure of the anterior chamber angle. For analysis of ASOCT measurements, the following parameters were calculated using the ImageJ program: (1) Angle opening distance (AOD 500 or AOD 750), the distance between a point on the cornea 500 or 750 μm from the scleral spur and the opposite point of the iris, and (2) trabecular-iris space area (TISA 500 or TISA 750), an area covering 500 or 750 μm located in the area bounded by the cornea and the iris [11] (Figure 1). All images obtained through ASOCT were evaluated for their quality according to the visibility of the scleral spur. In some subjects, scleral spur was not observed due to posterior shadowing, with strong signal formation at the corneoscleral junction. In other cases, despite the excellent visibility, a typical inward protrusion of the scleral spur was not observed on the inner surface of the sclera. Likewise, all images that could not identify the location of the scleral spur were excluded from the study.

The pRNFL thickness measurements in the 12 subfields (superotemporal, superior, superonasal, nasosuperior, nasal, nasoinferior, inferonasal, inferior, inferotemporal, temporo-inferior, temporal, and temporosuperior) were performed using RNFL thickness map analysis protocols. The mGCIPL thickness was automatically measured as the distance between the inner border of the ganglion cell layer and the outer border of the inner plexiform layer. After checking for segmentation error, the mGCIPL thickness map on the macula six sector grids was then obtained using the ganglion cell analysis algorithm, which provided the average of six sectors (superotemporal, superior, superonasal, inferonasal, inferior, and inferotemporal) of the elliptical annulus. All scans of the posterior segment were obtained with a minimum signal strength index of 50 and above.

**2.4. Statistical Analysis.** We performed all statistical analyses using SPSS for Windows version 18.0 (SPSS, Inc., Chicago, IL, USA). The Wilcoxon signed-rank test was used to determine changes in systemic parameters, such as body weight and blood pressure, and ophthalmic parameters, such as IOP, ACD, AL, and OCT measurements before and after HD. Continuous data were presented as the mean ± standard deviation. *P* values less than 0.05 were considered significant.

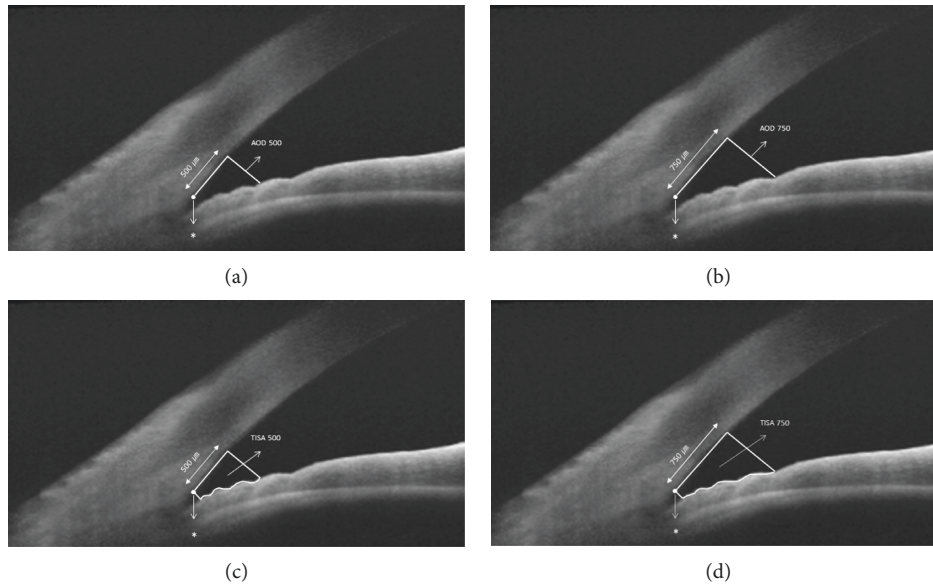


FIGURE 1: Measurement of quantitative angle parameters using ASOCT. (a, b) Angle opening distance (AOD). (c, d) Trabecular-iris space area (TISA). AOD 500 and 750 (angle opening distance): a distance between a point of the cornea which is 500 and 750  $\mu\text{m}$  away from the scleral spur and the opposite point of the iris. TISA 500 and 750 (trabecular-iris space area): an area covering 500 and 750  $\mu\text{m}$  located in the area bounded by the cornea and the iris.

### 3. Results

**3.1. Demographic and Clinical Characteristics.** A total of 20 ESKD patients undergoing HD participated in the study. Table 1 shows the demographic data and clinical characteristics of the included patients. The mean age of the patients was  $53.6 \pm 10.9$  years, and 10 men and 10 women were included. Hypertension was found in 14 patients (70.0%), and diabetes mellitus was found in eight patients (40.0%). The most common causes of HD were hypertensive (30.0%) and diabetic nephropathy (30.0%). Mean body weight was  $63.8 \pm 11.0$  kg before HD and  $61.0 \pm 11.2$  kg after HD. The decrease in body weight was statistically significant ( $P < 0.001$ , Wilcoxon signed-rank test). The mean systolic and diastolic blood pressures before HD were  $160.2 \pm 18.8$  mmHg and  $77.2 \pm 11.3$  mmHg, respectively. The systolic blood pressure after HD decreased significantly to  $149.5 \pm 20.4$  mmHg ( $P = 0.040$ ). However, diastolic blood pressure did not show a statistically significant change ( $P = 0.111$ ).

**3.2. Changes in Anterior Chamber Angle after Hemodialysis.** Table 2 shows changes in IOP, ACD, AL, and anterior chamber angle parameters before and after HD. IOP decreased significantly from  $17.5 \pm 3.4$  before HD to  $16.2 \pm 2.3$  after HD ( $P = 0.017$ ). ACD and AL showed little change after HD. Significant changes in parameters of the anterior chamber angle measured with ASOCT were observed. AOD 750 showed a statistically significant decrease from  $0.647 \pm 0.253$  mm before HD to  $0.581 \pm 0.249$  mm after HD ( $P = 0.005$ ). Similarly, TISA 750 also decreased significantly from  $0.326 \pm 0.123$  mm<sup>2</sup> to  $0.299 \pm 0.122$  mm<sup>2</sup> after HD ( $P = 0.007$ ). AOD 500 and TISA 500 also decreased after

TABLE 1: Demographic data and baseline clinical characteristics of patients.

| Characteristics                           | Numbers          |
|---|------------------|
| Age, years                                | $53.6 \pm 10.9$  |
| Sex, male:female                          | 10:10            |
| Hypertension                              | 14 (70.0%)       |
| Diabetes                                  | 8 (40.0%)        |
| Cause of HD                               |                  |
| Hypertensive nephropathy                  | 6 (30.0%)        |
| Diabetic nephropathy                      | 6 (30.0%)        |
| IgA nephropathy                           | 3 (15.0%)        |
| Polycystic kidney disease                 | 1 (5.0%)         |
| Unknown                                   | 4 (20.0%)        |
| Body weight before HD (kg)                | $63.8 \pm 11.0$  |
| Body weight after HD (kg)                 | $61.0 \pm 11.2$  |
| P value                                   | <0.001           |
| Systolic blood pressure before HD (mmHg)  | $160.2 \pm 18.8$ |
| Systolic blood pressure after HD (mmHg)   | $149.5 \pm 20.4$ |
| P value                                   | 0.040            |
| Diastolic blood pressure before HD (mmHg) | $77.2 \pm 11.3$  |
| Diastolic blood pressure after HD (mmHg)  | $83.2 \pm 10.7$  |
| P value                                   | 0.111            |

HD = hemodialysis.

HD, but the difference was not statistically significant ( $P = 0.061$  and  $P = 0.081$ , respectively).

**3.3. Peripapillary RNFL Thickness and Macular GCIPL Thickness before and after Hemodialysis.** Table 3 shows changes in pRNFL thickness and mGCIPL thickness after HD. Mean pRNFL thickness did not change significantly from  $98.1 \pm 15.2$   $\mu\text{m}$  before HD to  $98.8 \pm 15.3$   $\mu\text{m}$  after HD ( $P = 0.236$ ). The average mGCIPL thickness was measured

TABLE 2: Comparison of anterior chamber angle parameters before and after hemodialysis.

| Characteristics             | Before HD     | After HD      | <i>P</i> value |
|-----------------------------|---------------|---------------|----------------|
| IOP (mmHg)                  | 17.5 ± 3.4    | 16.2 ± 2.3    | 0.017          |
| ACD (mm)                    | 3.3 ± 0.6     | 3.2 ± 0.5     | 0.367          |
| AL (mm)                     | 23.5 ± 1.3    | 23.6 ± 1.3    | 0.927          |
| AOD 500 (mm)                | 0.459 ± 0.181 | 0.432 ± 0.187 | 0.061          |
| AOD 750 (mm)                | 0.647 ± 0.253 | 0.581 ± 0.249 | 0.005          |
| TISA 500 (mm <sup>2</sup> ) | 0.170 ± 0.065 | 0.162 ± 0.066 | 0.081          |
| TISA 750 (mm <sup>2</sup> ) | 0.326 ± 0.123 | 0.299 ± 0.122 | 0.007          |

HD = hemodialysis; IOP = intraocular pressure; ACD = anterior chamber depth; AL = axial length; AOD = angle open distance; TISA = trabecular-iris space area.

TABLE 3: Comparison of peripapillary retinal nerve fiber layer thickness and macular ganglion cell-inner plexiform layer thickness before and after hemodialysis.

| Characteristics      | Before HD    | After HD     | <i>P</i> value |
|----------------------|--------------|--------------|----------------|
| pRNFL thickness (μm) |              |              |                |
| Superotemporal       | 130.4 ± 33.7 | 132.6 ± 33.8 | 0.373          |
| Superior             | 106.8 ± 23.4 | 108.2 ± 25.5 | 0.456          |
| Superonasal          | 97.4 ± 18.4  | 98.8 ± 19.2  | 0.353          |
| Nasosuperior         | 81.5 ± 18.5  | 82.6 ± 20.1  | 0.610          |
| Nasal                | 68.0 ± 18.0  | 71.8 ± 15.2  | 0.858          |
| Nasoinferior         | 70.7 ± 15.5  | 73.2 ± 17.4  | 0.288          |
| Inferonasal          | 106.6 ± 24.4 | 105.8 ± 24.1 | 0.654          |
| Inferior             | 138.3 ± 33.1 | 131.3 ± 41.5 | 0.094          |
| Inferotemporal       | 132.6 ± 33.9 | 134.0 ± 35.7 | 0.401          |
| Temporoinferior      | 77.6 ± 21.0  | 80.2 ± 22.8  | 0.241          |
| Temporal             | 71.2 ± 15.7  | 72.1 ± 14.1  | 0.531          |
| Temporosuperior      | 95.1 ± 24.8  | 99.3 ± 30.8  | 0.141          |
| Average              | 98.1 ± 15.2  | 98.8 ± 15.3  | 0.236          |
| mGCIPL thickness     |              |              |                |
| Superotemporal       | 63.4 ± 7.3   | 63.5 ± 9.4   | 0.902          |
| Superior             | 63.3 ± 6.5   | 63.8 ± 8.8   | 0.520          |
| Superonasal          | 67.9 ± 7.5   | 67.6 ± 9.6   | 0.832          |
| Inferonasal          | 64.8 ± 9.2   | 65.4 ± 9.2   | 0.042          |
| Inferior             | 58.8 ± 7.1   | 59.6 ± 6.9   | 0.019          |
| Inferotemporal       | 63.3 ± 7.9   | 63.6 ± 8.7   | 0.501          |
| Average              | 63.6 ± 6.9   | 64.0 ± 8.0   | 0.499          |

HD = hemodialysis; pRNFL = peripapillary retinal nerve fiber layer; mGCIPL = macular ganglion cell-inner plexiform layer.

as  $63.6 \pm 6.9 \mu\text{m}$  before HD and  $64.0 \pm 8.0 \mu\text{m}$  after HD, which was also not statistically significant ( $P = 0.499$ ).

#### 4. Discussion

Our results showed a significant decrease in IOP and anterior chamber angle measurements after HD. There was significant decrease in AOD 750 and TISA 750, and AOD 500 and TISA 500 showed a tendency to decrease after HD. Mean pRNFL thickness and mGCIPL thickness did not show significant change after HD.

Because hemodynamic changes due to HD have been expected to occur in the retina and choroid, which are relatively blood-rich tissues in the eye, most OCT studies have focused on retinal thickness and choroidal thickness [7–10]. In addition, most ophthalmologic studies related to HD examined the change in IOP [6,12–18]. The changes in

IOP associated with HD have shown very diverse results, and various hypotheses have been reported to illustrate this variability. The structure of the anterior chamber angle, the site of aqueous humor release, may be an important factor to explain the change in IOP associated with HD. However, the analysis of anterior chamber angle images through ASOCT in HD patients has not yet been done. Although not HD, there has been a recent study of ASOCT in patients undergoing nocturnal intermittent peritoneal dialysis [19]. As a result, IOP decreased significantly, but no significant changes were observed in ASOCT parameters, such as AOD 500, AOD 750, TISA 500, and TISA 750, after nocturnal intermittent peritoneal dialysis. This was not consistent with our findings in HD patients.

In order to account for changes in the anterior chamber angle, consideration of IOP and aqueous humor is essential. Early studies have reported increased IOP due to increased production of aqueous humor [12, 20]. The reason for the elevation of IOP after HD was explained by the rapid decrease of plasma osmotic pressure or the increase of relative urea concentration in the aqueous humor, resulting in migration of extracellular fluid from the blood into the anterior chamber. Tawara and associates reported a change in IOP after HD between groups with and without compromise in aqueous outflow facility and observed a significant increase in IOP in the outflow obstruction group [21]. In the same way as the abovementioned studies, increased aqueous humor in the anterior chamber can increase IOP, which can be prevented by enhancing aqueous humor outflow. If there is no obstruction in aqueous outflow, IOP elevation will not occur due to this mechanism.

On the other hand, several studies recently reported a decrease in IOP after HD [7, 10, 16]. Tokuyama and associates evaluated the relationship between IOP and plasma colloid osmotic pressure [16]. In their study, IOP, plasma osmolality, and body weight decreased significantly after HD, but plasma colloid osmotic pressure showed a significant increase after HD. Significant correlations were found between changes in IOP and that of plasma colloid osmotic pressure, not between changes in IOP and that of plasma osmolality.

Our results showed significant decrease in IOP and body weight, which is similar to that of Tokuyama and associates. Unfortunately, we were unable to perform blood sampling before and after HD; therefore, plasma osmolality and plasma colloid osmotic pressure values could not be obtained. However, a decrease in body weight and hemodynamic changes, such as a decrease in systolic blood pressure, indirectly indicate a decrease in body fluid volume, which may lead to an increase in plasma colloid osmotic pressure. In addition, IOP elevation due to an abrupt decrease in plasma osmolality is not expected to occur due to the recent development of dialysis technology. This is supported by the recent decline in IOP observed in most HD studies.

Prior to the development of OCT, attempts were made to observe changes in the anterior chamber angle of HD patients through gonioscopy. Jaeger and associates reported a narrow angle in patients with acute elevation of IOP after HD [22]. De Marchi and associates reported that IOP was



elevated in patients with a narrow angle, whereas IOP did not change or decrease in patients with a normal angle [23]. In our study using ASOCT, the anterior chamber angle tended to be narrowed and the IOP decreased, which are different from previous studies. This discrepancy can be explained by the difference of interpretation according to cause and effect. As in other studies, narrow chamber angles may have the effect of increasing IOP by suppressing aqueous outflow, but our study suggests that a narrow angle was observed as a result of a decrease in aqueous humor, which leads to a decrease in IOP. As the plasma volume in the body decreases due to the exit of water from the plasma to the dialysate during HD, the concentration of plasma protein is relatively increased. As a result, the plasma colloid osmotic pressure is increased and water moves from the aqueous humor to the plasma, which leads to a decrease aqueous humor.

A decrease in aqueous humor can be expressed as a decrease in ACD, as well as a decrease in IOP and narrowing of the chamber angle. However, our results show that the ACD remained almost unchanged. This may suggest that changes in the anterior chamber angle, where the production and absorption of aqueous humor occur, are more vulnerable to changes in aqueous humor than to the central portion of the aqueous chamber. On the other hand, there may be discrepancies in the results of angle and center of anterior chamber due to differences in test methods. Since our ASOCT protocol cannot measure the ACD, we used the IOLmaster for ACD measurements. If it is possible to obtain an image for the entire anterior chamber, this error may be reduced.

In the present study, pRNFL thickness and mGCIPL thickness did not change after HD. These results were consistent with a previous study [24]. Demir and associates reported a decrease in RNFL thickness in chronic kidney disease patients receiving HD compared to the control group [25]. It is possible that RNFL thickness may be reduced in association with the death of retinal ganglion cells due to uremic optic neuropathy observed in chronic kidney disease and ischemic optic neuropathy caused by hypotension after HD [26, 27]. In this study, only the acute effects of HD were examined, which lead to no significant changes in pRNFL thickness or mGCIPL thickness.

Our study has some limitations. Firstly, as mentioned above, we could not measure changes in plasma osmolarity and plasma colloid osmotic pressure because we did not perform blood sampling before and after HD. Therefore, it was only possible to estimate these indirectly through changes in body weight and blood pressure. Secondly, IOP could not be measured with the Goldmann applanation tonometer, which is the gold standard method of IOP measurement. However, since the IOP measurements using TonoPen® were made in the bedside just before and immediately after HD, the interval between IOP measurements and HD was minimized, which made it possible to demonstrate the direct effect of HD on IOP. Furthermore, TonoPen has been shown to be as accurate as the Goldmann applanation tonometer when measuring IOP in adults with normal values [28]. Thirdly, because the study sample size is

small and enrolled patients had various underlying diseases, this result may be difficult to apply to all patients undergoing HD. Therefore, future studies should include a large number of patients in order to demonstrate the relationships between changes in IOP, anterior chamber angle, plasma osmolarity, and plasma colloid osmotic pressure after HD.

In conclusion, we suggest that loss of body fluids after HD causes a decrease in body weight and a decrease in blood pressure; as a result, water is moved from the anterior chamber to the plasma via elevated plasma colloid osmotic pressure. This leads to a decrease in IOP and anatomical narrowing of the anterior chamber. Our results are novel because the structural changes in the anterior chamber angle in HD patients were first demonstrated by ASOCT with changes in IOP.

### Data Availability

The data used to support the findings of this study are included within the article.

### Conflicts of Interest

The authors declare that they have no conflicts of interest.

### Authors' Contributions

Yong Un Shin and Ji Hong Kim contributed equally to this article as co-first authors.

### Acknowledgments

The authors would like to thank Biostatistical Consulting and Research Lab, Hanyang University, for assistance with statistical analysis. This research was supported by Basic Science Research Program through the National Research Foundation of Korea funded by the Ministry of Education (NRF-2017R1D1A1B03030905 and NRF-2017R1D1A1B03031934).

### References

- [1] P. Fauchald, "Transcapillary colloid osmotic gradient and body fluid volumes in renal failure," *Kidney International*, vol. 29, no. 4, pp. 895–900, 1986.
- [2] J. K. Leypoldt, A. K. Cheung, J. A. Delmez et al., "Relationship between volume status and blood pressure during chronic hemodialysis," *Kidney International*, vol. 61, no. 1, pp. 266–275, 2002.
- [3] L. Tomazzoli, R. De Natale, A. Lupo, and B. Parolini, "Visual acuity disturbances in chronic renal failure," *Ophthalmologica*, vol. 214, no. 6, pp. 403–405, 2000.
- [4] P. Diaz-Couchoud, F. D. Bordas, J. R. F. Garcia, E. M. Camps, and A. Carceller, "Corneal disease in patients with chronic renal insufficiency undergoing hemodialysis," *Cornea*, vol. 20, no. 7, pp. 695–702, 2001.
- [5] N. Klaassen-Broekema and O. P. van Bijsterveld, "Red eyes in renal failure," *British Journal of Ophthalmology*, vol. 76, no. 5, pp. 268–271, 1992.
- [6] E. Cecchin, S. De Marchi, and F. Tesio, "Intraocular pressure and hemodialysis," *Nephron*, vol. 43, no. 1, pp. 73–74, 1986.
- [7] J. W. Jung, M. H. Yoon, S. W. Lee, and H. S. Chin, "Effect of hemodialysis (HD) on intraocular pressure, ocular surface,

- and macular change in patients with chronic renal failure. Effect of hemodialysis on the ophthalmologic findings," *Graefe's Archive for Clinical and Experimental Ophthalmology*, vol. 251, no. 1, pp. 153–162, 2013.
- [8] F. Ulaş, Ü. Doğan, A. Keleş, M. Ertılav, H. Tekçe, and S. Çelebi, "Evaluation of choroidal and retinal thickness measurements using optical coherence tomography in non-diabetic haemodialysis patients," *International Ophthalmology*, vol. 33, no. 5, pp. 533–539, 2013.
- [9] O. Çelikay, S. Çalışkan, T. Biçer, N. Kabataş, and C. Gürdal, "The acute effect of hemodialysis on choroidal thickness," *Journal of Ophthalmology*, vol. 2015, Article ID 528681, 5 pages, 2015.
- [10] E. Chelala, A. Dirani, A Fadlallah et al., "Effect of hemodialysis on visual acuity, intraocular pressure, and macular thickness in patients with chronic kidney disease," *Clinical Ophthalmology*, vol. 9, pp. 109–114, 2015.
- [11] S. Radhakrishnan, J. See, S. D. Smith et al., "Reproducibility of anterior chamber angle measurements obtained with anterior segment optical coherence tomography," *Investigative Ophthalmology & Visual Science*, vol. 48, no. 8, pp. 3683–3688, 2007.
- [12] V. Sitprija, J. H. Holmes, and P. P. Ellis, "Changes in intraocular pressure during hemodialysis," *Investigative Ophthalmology & Visual Science*, vol. 3, pp. 273–284, 1964.
- [13] U. Gafter, M. Pinkas, J. Hirsch, J. Levi, and H. Savir, "Intraocular pressure in uremic patients on chronic hemodialysis," *Nephron*, vol. 40, no. 1, pp. 74–75, 1985.
- [14] H. Leiba, M. Oliver, M. Shimshoni, and Y. Bar-Khayim, "Intraocular pressure fluctuations during regular hemodialysis and ultrafiltration," *Acta Ophthalmologica*, vol. 68, no. 3, pp. 320–322, 1990.
- [15] S. M. Gutmann and N. D. Vaziri, "Effect of hemodialysis on intraocular pressure," *Artificial Organs*, vol. 8, no. 1, pp. 62–65, 1984.
- [16] T. Tokuyama, T. Ikeda, and K. Sato, "Effect of plasma colloid osmotic pressure on intraocular pressure during haemodialysis," *British Journal of Ophthalmology*, vol. 82, no. 7, pp. 751–753, 1998.
- [17] R. Hojs and D. Pahor, "Intraocular pressure in chronic renal failure patients treated with maintenance hemodialysis," *Ophthalmologica*, vol. 211, no. 6, pp. 325–326, 1997.
- [18] A. Pelit, A. Zümrütdal, and Y. Akova, "The effect of hemodialysis on visual field test in patients with chronic renal failure," *Current Eye Research*, vol. 26, no. 5, pp. 303–306, 2003.
- [19] K. L. Chong, A. Samsudin, T. C. Keng, T. A. Kamalden, and N. Ramli, "Effect of nocturnal intermittent peritoneal dialysis on intraocular pressure and anterior segment optical coherence tomography parameters," *Journal of Glaucoma*, vol. 26, no. 2, pp. e37–e40, 2017.
- [20] A. G. Watson and W. R. Greenwood, "Studies on the intraocular pressure during hemodialysis," *Canadian Journal of Ophthalmology*, vol. 1, no. 4, pp. 301–307, 1966.
- [21] A. Tawara, H. Kobata, K. Fujisawa, T. Abe, and Y. Ohnishi, "Mechanism of intraocular pressure elevation during hemodialysis," *Current Eye Research*, vol. 17, no. 4, pp. 339–347, 1998.
- [22] P. Jaeger, L. Morisod, J. P. Wauters, and R. Faggioni, "Prevention of glaucoma during hemodialysis by mannitol and acetazolamide," *New England Journal of Medicine*, vol. 303, no. 12, p. 702, 1980.
- [23] S. De Marchi, E. Cecchin, and F. Tesio, "Intraocular pressure changes during hemodialysis: prevention of excessive dialytic rise and development of severe metabolic acidosis following acetazolamide therapy," *Renal Failure*, vol. 11, no. 2–3, pp. 117–124, 1989.
- [24] S. J. Yang, Y. H. Han, G. I. Song, C. H. Lee, and S. W. Sohn, "Changes of choroidal thickness, intraocular pressure and other optical coherence tomographic parameters after haemodialysis," *Clinical and Experimental Optometry*, vol. 96, no. 5, pp. 494–499, 2013.
- [25] M. N. Demir, Ü. Ekşioğlu, M. Altay et al., "Retinal nerve fiber layer thickness in chronic renal failure without diabetes mellitus," *European Journal of Ophthalmology*, vol. 19, no. 6, pp. 1034–1038, 2009.
- [26] D. L. Knox, A. M. Hanneken, F. C. Hollows, N. R. Miller, H. L. Schick Jr., and W. L. Gonzales, "Uremic optic neuropathy," *Archives of Ophthalmology*, vol. 106, no. 1, pp. 50–54, 1988.
- [27] K. S. Servilla and G. C. Groggel, "Anterior ischemic optic neuropathy as a complication of hemodialysis," *American Journal of Kidney Diseases*, vol. 8, no. 1, pp. 61–63, 1986.
- [28] S. F. Kao, P. R. Lichter, T. J. Bergstrom, S. Rowe, and D. C. Musch, "Clinical comparison of the oculab tonopen to the goldmann applanation tonometer," *Ophthalmology*, vol. 94, no. 12, pp. 1541–1544, 1987.



Hindawi

Submit your manuscripts at  
[www.hindawi.com](http://www.hindawi.com)

