

# Anterior scleritis following intravitreal injections in a patient with rheumatoid arthritis

## A case report

So Jung Ryu, MD, Min Ho Kang, MD, PhD, Mincheol Seong, MD, PhD, Heeyoon Cho, MD, PhD, Yong Un Shin, MD, PhD\*

### Abstract

**Rationale:** Surgically induced scleritis is a rare complication following ophthalmologic surgery such as cataract surgery, pterygium excision, strabismus surgery, and retinal detachment repair. Rheumatoid arthritis (RA) is the connective tissue disease most commonly associated with scleritis.

**Patient concerns:** A 70-year-old woman visited our clinic with complaint of visual disturbance, ocular pain, and conjunctival injection in her right eye of 1 month's duration. She had a stable state of rheumatoid factor positive RA and had a history of multiple intravitreal injections placed in the symptomatic right eye due to age-related macular degeneration.

**Diagnoses:** Anterior scleritis induced by multiple intravitreal injections.

**Interventions:** Topical and systemic steroids were administered.

**Outcomes:** Her symptoms and signs were relieved and no significant recurrence has been occurred with the maintenance of low dose oral steroid.

**Lessons:** Surgically induced scleritis can also be induced by not only major surgical trauma but also by relatively minor trauma such as intravitreal injection (especially in patients who have connective tissue disease such as RA).

**Abbreviations:** CRP = C-reactive protein, ESR = erythrocyte sedimentation rate, OCT = optical coherence tomography, RA = rheumatoid arthritis, VEGF = vascular endothelial growth factor.

**Keywords:** intravitreal injection, rheumatoid arthritis, scleritis

## 1. Introduction

Scleritis is a usually painful ocular inflammatory disorder, which is associated with systemic collagen vascular disease and it has been reported that approximately 50% of patients afflicted with systemic connective tissue disease are also afflicted with

scleritis.<sup>[1,2]</sup> However, the association between surgically induced scleritis and systemic connective tissue disease has not been researched on a large scale because of the rarity of the disease. Previous reports have demonstrated a high incidence of rheumatic disease among surgically induced, necrotizing scleritis patients.<sup>[3]</sup> There were several studies about scleritis following cataract surgery in patients with rheumatoid arthritis (RA) and ankylosing spondylitis,<sup>[4–7]</sup> trabeculectomy in a patient with Wegener granulomatosis,<sup>[3]</sup> and pterygium excision in a patient with RA.<sup>[8]</sup>

Intravitreal injections are widely used to treat various retinal diseases and is a relatively safe procedure that seldom produces complications such as endophthalmitis and elevated intraocular pressure. As noted above, we encountered a case of a recurrent anterior diffuse scleritis following intravitreal anti-vascular endothelial growth factor (anti-VEGF) injection, which was a relatively minimal surgical procedure compared with other reported cases.

## 2. Case report

A 70-year-old woman visited our outpatient department with complaint of visual disturbance in her right eye of 1 month's duration. Previously, she had been diagnosed with age-related macular degeneration (about 7 years before), and had a history of 6 intravitreal bevacizumab injections placed in the symptomatic right eye. Her last injection was performed 2 months prior. She also underwent cataract surgery, bilaterally, approximately 2 years ago and experienced no postoperative complications. On

Editor: Dinesh Garg.

SJR and MHK contributed equally to this article as cofirst authors.

Funding/support: This research was supported by Basic Science Research Program through the National Research Foundation of Korea funded by the Ministry of Education (NRF-2017R1D1A1B03030905).

Informed consent was obtained from the patient for publication of this case report and its related images.

The authors declare no conflicts of interest.

Department of Ophthalmology, Hanyang University College of Medicine, Seoul, Korea.

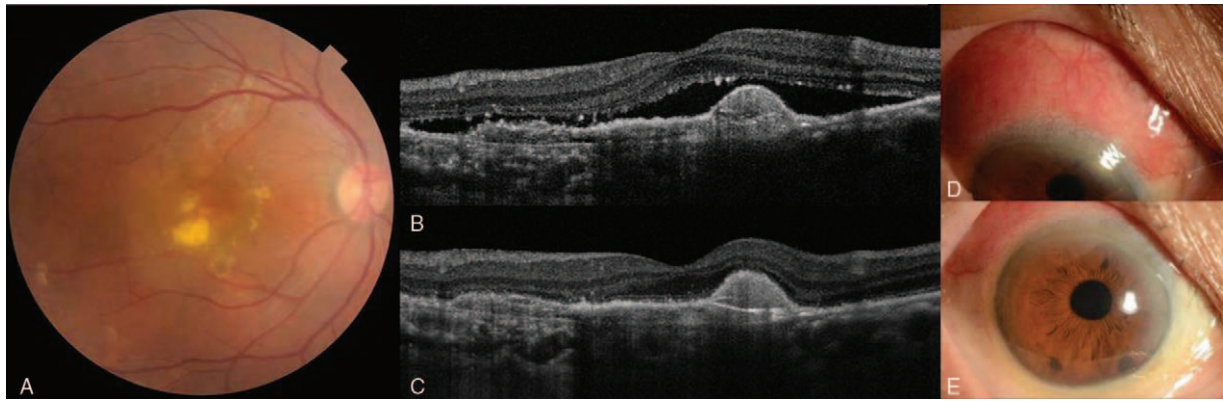
\* Correspondence: Yong Un Shin, Department of Ophthalmology, Hanyang University College of Medicine, #222, Wangimni-ro, Seongdong-gu, Seoul 04763, Korea (e-mail: syu2000@hanmail.net).

Copyright © 2017 the Author(s). Published by Wolters Kluwer Health, Inc. This is an open access article distributed under the terms of the Creative Commons Attribution-Non Commercial-No Derivatives License 4.0 (CCBY-NC-ND), where it is permissible to download and share the work provided it is properly cited. The work cannot be changed in any way or used commercially without permission from the journal.

Medicine (2017) 96:47(e8925)

Received: 31 July 2017 / Received in final form: 31 October 2017 / Accepted: 7 November 2017

<http://dx.doi.org/10.1097/MD.0000000000008925>



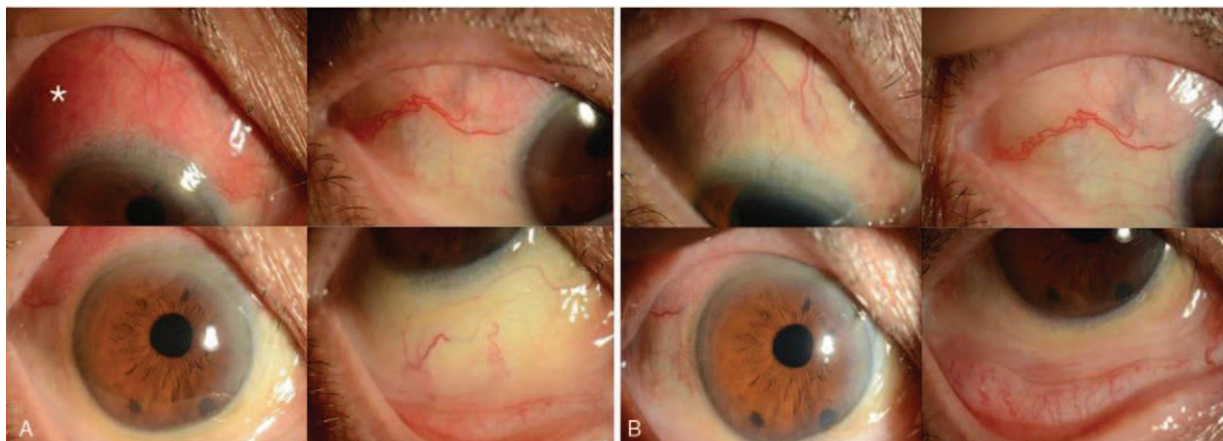
**Figure 1.** Exudation was observed on fundus photography (A) and active macular choroidal neovascularization and subretinal fluid were observed on optical coherence tomography (B). Following intravitreal injection, subretinal fluid was markedly decreased on optical coherence tomography (C), but anterior diffuse scleritis occurred (D, E).

medical history, she had a stable state of rheumatoid factor positive RA since 2001. She also had a history of interstitial lung disease related to systemic connective tissue disease. Her recent medications for RA consisted of methotrexate 10 mg per week, sulfasalazine 500 mg twice a day, hydroxychloroquine sulfate 200 mg, and folic acid 1 mg once-daily.

At first visit, the best corrected visual acuity of the affected eye was 20/40. Subretinal fluid and exudate were observed on slit-lamp examination and active macular choroidal neovascularization was observed on fluorescein angiography and optical coherence tomography (OCT) (Fig. 1). We made a plan to perform monthly 3 loading intravitreal aflibercept (EYLEA; Regeneron, Tarrytown, NY) injections. All injection sites were performed at 3 mm posterior to limbus between 2:00 and 3:00 o'clock of the right eye. After injection, she was trained to use antibiotic eye drops every 3 hours for a week. There were no injection-related complications until the second intravitreal injection.

At the time of the third injection, mild conjunctival injection around the injection site was observed, but the third injection was

performed anyway because she did not complain of any ocular symptoms. After 3 weeks, she complained of moderate ocular pain, tenderness, and red eye. The area of conjunctival injection was widely spread from 10:00 to 2:00 o'clock and encompassed the injection site. We diagnosed anterior diffuse scleritis based on clinical findings, including scleral edema and dilatation of the deep episcleral vascular plexus adjacent to the injection site, as revealed by slit lamp examination (Fig. 2A). The B-scan showed no sign of posterior scleral thickening. For the treatment of anterior scleritis, oral prednisolone (30 mg/day for 1 week) and steroid eye drops (loteprednol etabonate 0.5%, 4 times a day) were prescribed. One week later, the conjunctival injection afflicting the right eye was noted to have decreased, and her symptoms were markedly improved (Fig. 2B). Both oral and topical steroids were tapered and then suspended completely for 2 months. According to her rheumatology medical record at the time of the third intravitreal injection, her RA was well controlled [C-reactive protein (CRP) was 8 mg/dL and erythrocyte sedimentation rate (ESR) was 14 mm/h].



**Figure 2.** Anterior segment photos (A) show marked injection (asterisk) around the intravitreal injection site in the right eye. The patient complained of tenderness to palpation, and photophobia. There was scleral edema and dilatation of the deep episcleral vascular plexus on slit lamp examination and no signs of corneal infiltrates, thinning, and ulceration. Anterior segment photos (B) show decreased scleral edema and dilatation of the deep episcleral plexus after treatment for anterior diffuse scleritis, compared with the previous signs on the left. The subjective symptoms such as ocular pain and photophobia in her right eye resolved, as well.

Even if she underwent monthly 3 loading intravitreal aflibercept injections, subretinal fluid was still observed on OCT in the right eye. Because no scleritis-related symptoms and signs were observed, a fourth intravitreal aflibercept injection was performed at an inferotemporal site (4:00–5:00 o'clock). However, the scleritis recurred 1 week after the injection was placed. We again initiated steroid therapy and prescribed oral prednisone and a topical steroid, and her scleritis symptoms were resolved 1 week later. After that, her scleritis recurred after every intravitreal injection (regardless of injection site), and was consistently relieved by steroid medication. After the eighth intravitreal injection, a mild scleritis still persisted despite the absence of additional intravitreal injections; therefore, low-dose oral prednisolone (5–10mg/day) was maintained to prevent exacerbation or aggravation of the scleritis. We received informed consent from the patients for this report.

### 3. Discussion

Scleritis is an inflammatory ocular disorder that is often associated with both ocular complications and systemic diseases.<sup>[2]</sup> RA is a chronic systemic autoimmune disease with several characteristic findings such as arthritis of small joints, a positive test for serum rheumatoid factor, and is the most common connective tissue disorder, which is associated with scleral disease.<sup>[9]</sup>

Surgically induced scleritis is a rare complication but can sometimes be observed following a variety of procedures such as cataract extraction,<sup>[4–7,10]</sup> pterygium excision,<sup>[11]</sup> strabismus surgery,<sup>[12]</sup> and retinal detachment repair surgery.<sup>[3]</sup> There have been few reports that have explored a possible relationship between surgically induced scleritis and systemic autoimmune disease. Up to 90% of patients who had been diagnosed with surgically induced necrotizing scleritis were later additionally treated due to underlying systemic autoimmune disorder.<sup>[13]</sup> Subtypes of scleritis following surgery can be necrotizing, nodular, or diffuse.

The pathophysiology, the precise etiology, of surgically induced scleritis is unknown, but some have hypothesized that the condition represents a hypersensitivity reaction.<sup>[14]</sup> Fong et al<sup>[15]</sup> suggested that scleritis is considered a type III immune complex reaction because immune complex deposition and neutrophil infiltration were observed in the vascular walls in eyes with scleritis. In surgically induced necrotizing scleritis, surgical trauma may activate, or induce, the scleral fibroblasts to produce complement component C1, which can induce the cascade of vascular permeability and chemotaxis of inflammatory cells. Also, human leukocyte antigen-DR expression as well as an increase of interleukin-2 receptor expression can be enhanced on the T-cells, suggesting an active cell-mediated immune response. In patients with RA, Perez et al<sup>[6]</sup> surmised that deposition of the immune complexes in the scleral vessels can be stimulated by the surgical trauma.<sup>[6]</sup> We also presumed that the immune reaction might be more vigorous in patients who already have systemic autoimmune disorders such as RA. O'Donoghue et al<sup>[3]</sup> presumed that the hypersensitivity reaction was related to postsurgical scleritis based on their report that scleritis occurs more frequently after 2 or more surgeries than after a single surgery. Further studies will be required to confirm the cause of surgically induced scleritis in patients with systemic connective tissue diseases such as RA.

In a previous study of 70 patients with RA, there was no surgically induced scleritis following a total of 86 cataract extractions.<sup>[13]</sup> But we experienced a case of anterior diffuse

scleritis in a patient with RA following intravitreal injection, which is considered a minimally invasive procedure (compared with cataract surgery). We thought that this might be due to the difference in surgical procedure. In cataract surgery, many surgeons select to perform a clear cornea incision. Therefore, the conjunctival blood vessels may be intact, but with the introduction of an intravitreal injection, the conjunctival vessels could be traumatized and the recurrent contact with blood vessels could certainly induce a hypersensitivity reaction leading to scleritis.

The activity of RA is correlated with serum titers of rheumatoid factors, ESR, and CRP and patients presenting with an increase in these values have more severe and progressive disease with extra-articular manifestations.<sup>[16]</sup> Matsuo et al<sup>[4]</sup> reported that rheumatoid factor, one of the important values indicating the activity of the disease, was related to postsurgical inflammation. The persistence of aqueous inflammation 1 month after cataract extraction and intraocular lens implantation in RA patients had a significant correlation with the elevated antinuclear antibody titers of rheumatoid factor.<sup>[4]</sup> We also reviewed laboratory findings of our case to identify which systemic factors could influence the occurrence of her recurrent scleritis. However, the state of her RA had been stable based on her symptoms, the level of CRP, and ESR since her first visit to our clinic. Although we did not routinely check the rheumatoid factor titer, we did not reach a conclusion about the aggravation of RA and her recurrent scleritis.

Management of scleritis varies depending on the type and extent of disease but commonly, systemic corticosteroids or nonsteroidal anti-inflammatory drugs are used in the treatment of anterior diffuse scleritis.<sup>[17]</sup> The initial dosage of oral prednisolone should be calibrated with the severity of inflammation, generally from 20 to 60 mg daily.<sup>[18]</sup> Our patient's symptoms and signs were relieved with oral prednisolone but recurred following each and every injection. Especially, the scleritis in our case recurred in areas where scleritis had occurred first, even if we injected at other sites in the eye. It remains to be seen if this case of recurrent diffuse scleritis was a fluctuation of previous scleritis, or a subsequent recurrence due to intravitreal injection. Because patients rarely experience side effects from systemic corticosteroids, we maintained the patient on a low-dose oral prednisolone (5–10 mg/day) to prevent further aggravation of scleritis. There has been no significant recurrence since.

### 4. Conclusion

Intravitreal injection, which is relatively minor surgical trauma, could induce anterior scleritis in patients with RA. Repeated intravitreal injections may contribute to the occurrence of scleritis due to a hypersensitivity reaction. Intravitreal injection-induced scleritis can be easily overlooked, therefore close attention is required in the treatment of retinal diseases using intravitreal injection in those cases where the patient is concurrently afflicted with RA. If repeated and regular intravitreal injections are necessary for symptom control in patients with injection-related scleritis, a course of low-dose corticosteroids or other immunosuppressants could be helpful in preventing recurrence and aggravation.

### References

- [1] Akpek EK, Thorne JE, Qazi FA, et al. Evaluation of patients with scleritis for systemic disease. *Ophthalmology* 2004;111:501–6.
- [2] Wilhelmus K. Scleritis Associated with Rheumatoid-Arthritis and with Other Systemic Immune-Mediated Diseases-Discussion. Vol 101. Philadelphia, PA: Lippincott-Raven Publ; 1994:1287–1288.

- [3] O'Donoghue E, Lightman S, Tuft S, et al. Surgically induced necrotizing sclerokeratitis (SINS): precipitating factors and response to treatment. *Br J Ophthalmol* 1992;76:17–21.
- [4] Matsuo T, Fujiwara M, Matsuo N. Inflammation after cataract extraction and intraocular lens implantation in patients with rheumatoid arthritis. *Br J Ophthalmol* 1995;79:549–53.
- [5] Maffett MJ, Johns KJ, Parrish CM, et al. Sterile corneal ulceration after cataract extraction in patients with collagen vascular disease. *Cornea* 1990;9:279–85.
- [6] Perez VL, Azar DT, Foster CS. Sterile corneal melting and necrotizing scleritis after cataract surgery in patients with rheumatoid arthritis and collagen vascular disease. *Semin Ophthalmol* 2002;17:124–30.
- [7] Karia N, Doran J, Watson SL, et al. Surgically induced necrotizing scleritis in a patient with ankylosing spondylitis. *J Cataract Refract Surg* 1999;25:597–600.
- [8] Kim MJ, Joo CK. A case of enucleation due to extensive necrotizing scleritis after pterygium excision in a rheumatoid arthritis patient. *J Korean Ophthalmol Soc* 1998;39:777–83.
- [9] Okhravi N, Odufuwa B, McCluskey P, et al. Scleritis. *Surv Ophthalmol* 2005;50:351–63.
- [10] Scott JA, Clearkin LG. Surgically induced diffuse scleritis following cataract surgery. *Eye (Lond)* 1994;8:292–7.
- [11] Gokhale NS, Samant R. Surgically induced necrotizing scleritis after pterygium surgery. *Indian J Ophthalmol* 2007;55:144–6.
- [12] Kaufman LK, Folk ER, Miller MT, et al. Necrotizing scleritis following strabismus surgery for thyroid ophthalmopathy. *J Pediatr Ophthalmol Strabismus* 1989;26:236–8.
- [13] Jones RR, Maguire LJ. Corneal complications after cataract surgery in patients with rheumatoid arthritis. *Cornea* 1992;11:148–50.
- [14] Watson P. Doyne Memorial Lecture, 1982. The nature and the treatment of scleral inflammation. *Trans Ophthalmol Soc U K* 1982;102:257–81.
- [15] Fong LP, Sainz de la Maza M, Rice BA, et al. Immunopathology of scleritis. *Ophthalmology* 1991;98:472–9.
- [16] Fauci AS. *Harrison's Principles of Internal Medicine*. Vol 2. Medical Publishing Division, McGraw-Hill:2008.
- [17] Jabs DA, Mudun A, Dunn J, et al. Episcleritis and scleritis: clinical features and treatment results. *Am J Ophthalmol* 2000;130:469–76.
- [18] Smith JR, Mackensen F, Rosenbaum JT. Therapy insight: scleritis and its relationship to systemic autoimmune disease. *Nat Clin Pract Rheumatol* 2007;3:219–26.