

Congenital Hypoplasia of the Medial Hallucial Sesamoid with Avascular Necrosis: A Case Report¹

선천성 안쪽종자뼈 형성부전과 무혈성 괴사: 증례 보고¹

Yoonah Song, MD¹, Seunghun Lee, MD¹, Chan-Bum Choi, MD², Kyung Bin Joo, MD¹,
Jeong Ah Ryu, MD³, Jiyeon Bae, MD⁴

Departments of ¹Radiology, ²Rheumatology, Hanyang University College of Medicine, Seoul Hospital, Seoul, Korea

³Department of Radiology, Hanyang University College of Medicine, Guri Hospital, Guri, Korea

⁴Department of Pathology, National Police Hospital, Seoul, Korea

Avascular necrosis of the hallucial sesamoids is an uncommon cause of metatarsalgia, and the congenital absence of the medial sesamoid is also a rarely reported condition in the podiatric literature. It must be distinguished from other painful conditions of the sesamoid due to the opposite direction of treatment. To our knowledge, there is no reported case of congenital hypoplasia of the medial sesamoid with osteonecrosis. We report a case of nontraumatic metatarsal pains with progressive sclerosis and fragmentation of the medial sesamoid on serial radiographs, magnetic resonance imaging, and ultrasonography with an incidental finding for the absence of contralateral medial sesamoid in a 33-year-old female.

Index terms

Sesamoid Bones
Congenital
Absence
Osteonecrosis

INTRODUCTION

Painful conditions of the first metatarsophalangeal (MTP) joint include trauma, arthritis, infection, and ischemia (1). Sesamoid bone disorders are among the causes and can be difficult to diagnose. Avascular necrosis of the hallucial sesamoids is an uncommon cause of metatarsalgia. We present a patient complaining for pain on the plantar aspect of the right MTP joint, she was found to have congenital hypoplasia of the medial sesamoid with avascular necrosis. Progressions of fragmentation and increased areas of demineralization on the right medial sesamoid were shown on serial radiographs. Additional ultrasonography and magnetic resonance imaging (MRI) was done to exclude other painful conditions of the sesamoid. We must be aware of the possibilities for osteonecrosis of the sesamoid in patients with plantar pains to the first MTP joint because of the

opposite direction of treatments. To the best of our knowledge, no case of congenital hypoplasia of the medial sesamoid with osteonecrosis has yet been reported.

We report a rare case of congenital hypoplasia of the medial hallucial sesamoid with osteonecrosis.

CASE REPORT

A 33-year-old female patient visited our hospital; she was presented with pain under the plantar aspect of the first MTP joint of the right foot for the past year. The patient indicated that the pain became aggravated approximately one month earlier, and she had received treatments with medication at an outside hospital. However, the patient suffered sustained pain without improvements. A review of her systems was not remarkable. Physical examinations showed tenderness at the first right MTP joint plantar aspect and

Received June 21, 2013; Accepted July 16, 2013

Corresponding author: Seunghun Lee, MD
Department of Radiology, Hanyang University College of Medicine, Seoul Hospital, 222 Wangsimni-ro, Seongdong-gu, Seoul 133-792, Korea.
Tel. 82-2-2290-9164 Fax. 82-2-2293-2111
E-mail: radsh@medimail.co.kr

This is an Open Access article distributed under the terms of the Creative Commons Attribution Non-Commercial License (<http://creativecommons.org/licenses/by-nc/3.0>) which permits unrestricted non-commercial use, distribution, and reproduction in any medium, provided the original work is properly cited.

symptoms worsened on a weight bearing position. No gross deformity was observed in the right foot, and there was no history of trauma or previous surgery on the foot. Her medical history was unremarkable. A complete neurological examination did not reveal any local motor or sensory deficits. There was no local evidence of inflammation. The erythrocyte sedimentation rates and the serum uric acid levels were normal, as were the other standard laboratory tests.

Initial anteroposterior and lateral plain radiographs of both feet (Fig. 1B) showed an absence of the medial hallucial sesamoid on the left and subtle increased density in the first right MTP area. There was no evidence of a fracture line or abnormal soft tissues swelling. We suspected the possibilities of avascular necrosis or stress fracture of the medial sesamoid; therefore, further evaluation was done. Ultrasonography of the right foot (Fig. 2) showed multiple echogenic calcifications around the medial

hallucial sesamoid with adjacent subcutaneous edema. A color Doppler image showed increased focal vascularity in the medial hallucial sesamoid. However, there was no evidence of periosteal thickening with an adjacent hypoechoic fluid collection which previously reported features on stress fracture (2). We considered the possibilities of calcific tendinitis of the flexor hallucis brevis tendon or avascular necrosis of the medial hallucial sesamoid in the differential diagnoses. An additional sesamoid view (Fig. 1C) was done, which was an oblique coronal radiograph in which the beam is directed tangential to the metatarsos-sesamoid articulation, allowing direct visualization of the joint without osseous overlap (3). The sesamoid view of the right foot showed hypoplasia of the medial sesamoid around the first MTP joint with irregular bony fragmentations and adjacent soft tissues swelling. There was no evidence of bony erosion in the distal phalanx. At the second visit to our hospital, she brought a sim-

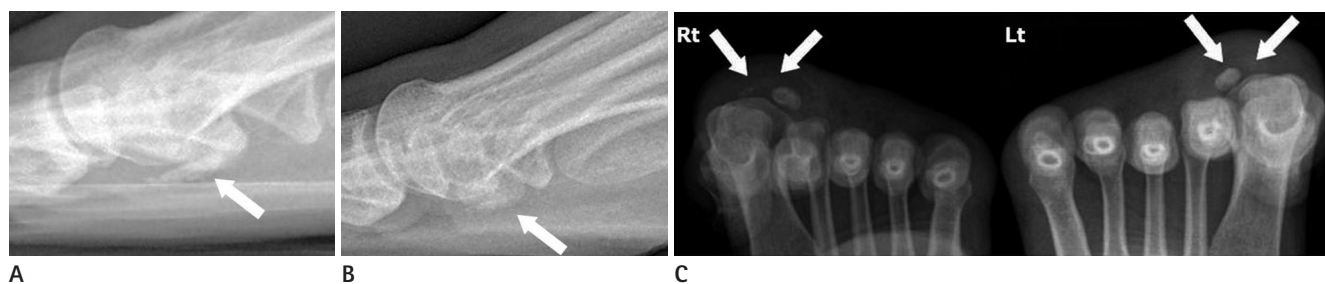


Fig. 1. Plain radiographs of the right foot who a 33-year-old woman with plantar pain to the right first metatarsophalangeal joint. A comparison of two radiographs at interval changes of a year; the medial sesamoid collapsed and had more areas of demineralization with fragmentation. **A.** Initial right lateral ankle radiograph at the outside hospital demonstrates flattening of the medial sesamoid with sclerosis (arrow). **B.** A year after initial lateral radiograph demonstrates a more collapsed medial sesamoid with increased areas of demineralization (arrow). **C.** An additional sesamoid view demonstrates the absence of the left medial sesamoid (arrows) and hypoplasia of the right medial sesamoid (arrows) with fragmentation and adjacent soft tissue swelling.

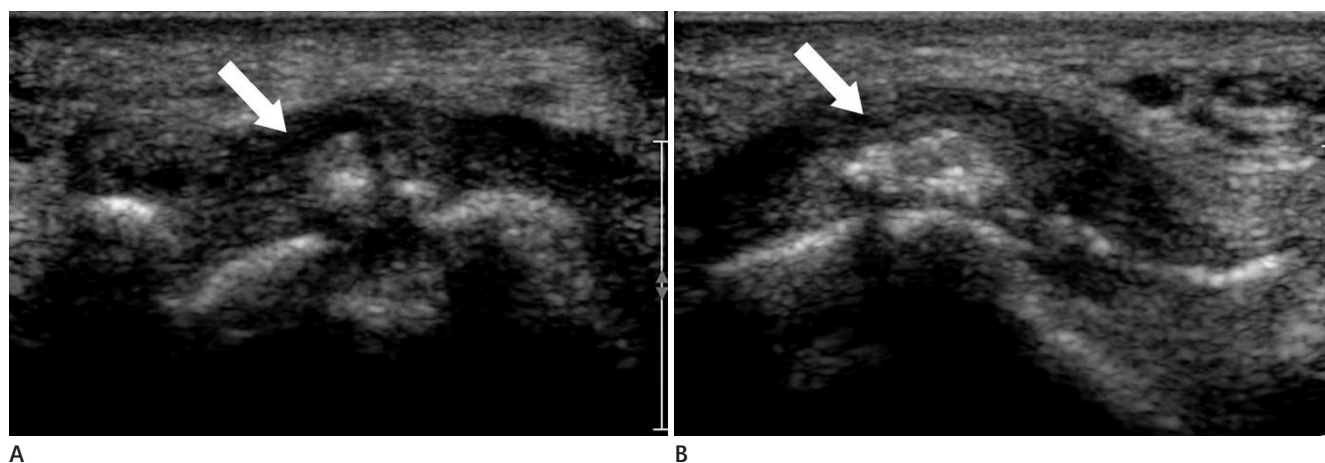


Fig. 2. Ultrasonography of the right foot. **A.** A transverse scan shows multiple echogenic nodules of the medial sesamoid (arrow) with fragmentation. **B.** A longitudinal scan shows an irregular surface of the medial sesamoid (arrow) with multiple echogenic nodules.

ple radiograph which was done at an outside hospital a year ago. The right ankle lateral radiograph at that time (Fig. 1A) showed a relatively small sized medial sesamoid with sclerosis and flattening. Compared with the current radiograph, the medial sesamoid collapsed and had more areas of demineralization with fragmentations. The patient was asymptomatic a year ago; thus, we considered that the radiographs of the outside hospital were the clues of hypoplasia for the medial sesamoid. Furthermore, most of the reported cases on congenital absence of the sesamoid in the first MTP joint displayed the tendency to be bilateral, thus, it could be easily recognized as hypoplasia associated with contralateral absence of the sesamoid bone (3). A progression of avascular necrosis with hypoplasia of the medial sesamoid was possible. MRI showed a fragmented medial hallucial sesamoid with cancellous marrow edema. The lesion showed a low signal intensity on T1-weighted images (T1WI), a heterogeneously low to intermediate signal intensity on the T2-weighted images (T2WI), and focal intense enhancement on fat-suppressed T1WI (Fig. 3). An additional finding was the absence of a left medial hallucial sesamoid. These MRI findings may be nonspecific, but according to a combination of the radiological features and the patient's clinical courses, the diagnosis was congenital hypoplasia of the right medial hallucial sesamoid with osteonecrosis and congenital absence of the left medial hallucial sesamoid.

The patient subsequently underwent conservative treatment with a metatarsal pad and nonsteroidal anti-inflammatory agents for two months. Despite the treatment, she complained of sus-

tained pains on the right foot. We recommended surgical treatment, but, unfortunately, despite our best attempts, this patient neglected to follow-up.

DISCUSSION

Avascular necrosis of the hallucial sesamoids is an uncommon cause of metatarsalgia and usually the last diagnosis of plantar pains to the first MTP joint. Most patients are adolescents or young adults, and women are more often affected than men. Patients typically complain for pains on the plantar aspect of the first MTP joint with insidious onset. Aggravating factors include the use of high-heeled shoes, microtrauma, sport activities such as track-and-field or dancing, and foot alignment disorders such as pes cavus and valgus of the hindfoot (3). Avascular necrosis of the small carpal and tarsal bones of the metacarpals is chiefly related to local ischemia caused by trauma or microtrauma (4). Radiographs of both feet should be taken for a comparative study. Typical imaging features of the radiographs are heterogeneously striped sclerosis, flattening of the sesamoid bone, and areas of demineralization (5). Fragmentation into two or more pieces is common, and a multitude of tiny fragments yielding a "bone dust" appearance can be seen. The classic radiographic signs do not appear until 6-12 months after the onset of pain; therefore, serial radiographs are often necessary to evaluate the progressions of the disease. Although rarely is a pre-injury radiograph available in helping to differentiate a partite sesamoid and a fracture, increased separation between fragments

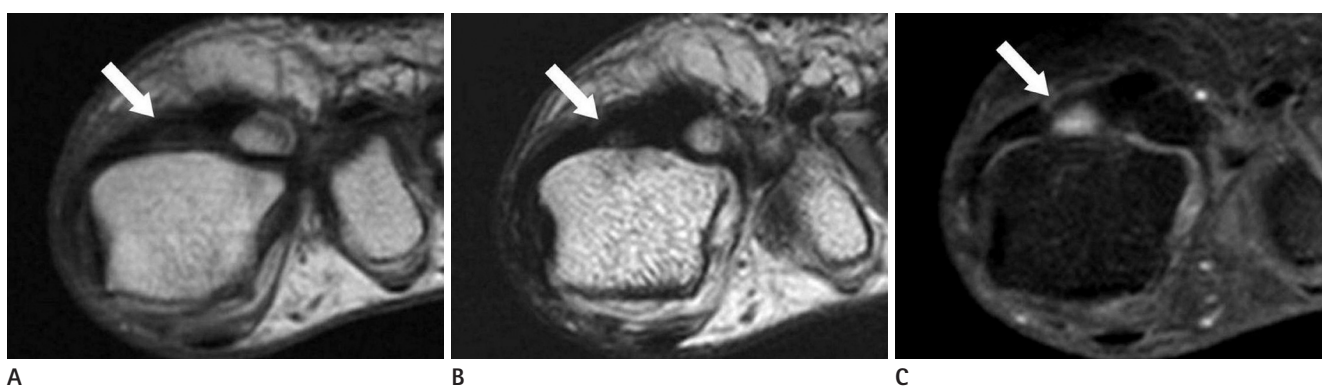


Fig. 3. Magnetic resonance image (MRI) of the right foot.

A. T1-weighted coronal MR image demonstrates the low signal intensity of the right medial sesamoid (arrow).

B. T2-weighted coronal MR image demonstrates heterogeneously low to intermediate signal intensity with fragmentation of the right medial sesamoid (arrow).

C. On gadolinium enhanced, fat-suppressed T1-weighted coronal MR image demonstrates patchy localized signal enhancement seen within the medial sesamoid (arrow). These findings reflect avascular necrosis of the medial sesamoid.

can be a definite finding for the presence of a disruption on a partite sesamoid (6).

Ultrasonography is not yet used routinely to diagnose avascular necrosis. Although sonography is not the golden standard of choice to diagnose bone disorders, in recent years, a number of studies have been performed describing the use of sonography for the diagnosis of peripheral bone fractures. A small periosteal elevation in the area of the fractured site with a small fluid collection and adjacent soft tissues edema has shown sonographic signs of a stress fracture which was not shown in our case (2). MR imaging will show the abnormality of the involved sesamoid with bone marrow edema at the time of the initial symptoms. Nonspecific, low signal intensity on T1WI and high signal intensity on T2WI are seen as avascular necrosis, sesamoiditis, or early stress fractures. Sesamoiditis is a descriptive term referring to any painful inflammatory conditions of the sesamoids, and it may be associated with stress related marrow edema, stress fractures, or even an acute fracture of one or both sesamoids. Early stress fractures of the sesamoids include irregular margins with unequal separation of the sesamoidal fragments, or evidence of periosteal new bone formation. Late MR imaging findings include fragmentation and areas of heterogeneous signal intensities on T1WI, and T2WI representing areas of sclerosis with bone marrow edema, which is a differential point of avascular necrosis among the other disease categories (3). In particular, the fragmentation of multiple pieces argues against a fracture, and the normal appearance of the neighboring soft tissues as seen in our case is unlikely to create an infection.

The sesamoids typically appear during the fifth and eighth week of fetal development. It has been documented that ossification is completed between 9 and 14 years-of-age (1). Multiple ossification centers have been described for the sesamoid bones, and it has been suggested that vascular insults to one or more of the centers before the completion of ossification that explains the formation of multipartite sesamoids, thus, it is considered to be an incomplete fusion of the ossification centers (7). The hallucal sesamoid complex is composed of two separate sesamoids: the medial and lateral sesamoids. More weight bearing occurs on the medial sesamoid bone, which is more susceptible to trauma (8). The medial sesamoid is the larger and longer of the two, and it is embedded within the medial head of the flexor hallucis brevis tendon (3). Generally, the sizes and the morphology of

the sesamoids are variables. The sesamoid size was quantitated, and it was reported that the medial sesamoid averaged 9 to 11 mm in width and 12 to 15 mm in length. The lateral sesamoid was noted to have an average width of 7 to 9 mm and an average length of 9 to 10 mm (6).

The hallucal sesamoid complex receives majority of its blood supply from either the plantar arch or from the medial plantar artery with each sesamoid typically supplied by a single artery that enters the sesamoid from a proximal and plantar direction. There is very little collateral blood supply, and little to no recurrent supply. This configuration of the blood supply may play an important role in certain pathologic conditions such as avascular necrosis (3). Therefore, the course and distribution of the arterial blood supply to the sesamoids might have a bearing on the development of avascular necrosis following injury (6). Only when one blood vessel supplies a sesamoid, the fracture may be at a greater risk for avascular necrosis or nonunions.

The treatment of choice for avascular necrosis on the sesamoid complex is a conservative therapy and usually the use of padding to the area decreases the weight bearing forces. Casting has also been considered to reduce the stresses on the sesamoid complex. If the pain lasts longer than six months despite appropriate medical treatments, a partial or total sesamoidectomy can be performed (9).

Congenital absence of the hallux sesamoid bones also occurs rarely. When it does, it is associated with chronic sesamoiditis, painful bipartite sesamoid bones, and chronic fracture nonunions (10). In our patient, it was purely an incidental finding, since the radiographic findings did not correlate with the symptoms reported.

In conclusion, clinicians and radiologists must be aware of the possibilities for osteonecrosis of the sesamoid in patients with plantar pains to the first MTP joint because of the opposite direction of treatments.

REFERENCES

1. Karasick D, Schweitzer ME. Disorders of the hallux sesamoid complex: MR features. *Skeletal Radiol* 1998;27:411-418
2. Bodner G, Stöckl B, Fierlinger A, Schocke M, Bernathova M. Sonographic findings in stress fractures of the lower

- limb: preliminary findings. *Eur Radiol* 2005;15:356-359
3. Sanders TG, Rathur SK. Imaging of painful conditions of the hallucal sesamoid complex and plantar capsular structures of the first metatarsophalangeal joint. *Radiol Clin North Am* 2008;46:1079-1092, vii
 4. Lafforgue P. Pathophysiology and natural history of avascular necrosis of bone. *Joint Bone Spine* 2006;73:500-507
 5. Toussirot E, Jeunet L, Michel F, Kantelip B, Wendling D. Avascular necrosis of the hallucal sesamoids update with reference to two case-reports. *Joint Bone Spine* 2003;70:307-309
 6. Coughlin MJ. Sesamoids and Accessory Bones of the Foot. In Roger AM. *Surgery of the foot and ankle, 8th ed.* Philadelphia, PA: Mosby, 2007:531-543
 7. Kanatli U, Ozturk AM, Ercan NG, Ozalay M, Daglar B, Yetkin H. Absence of the medial sesamoid bone associated with metatarsophalangeal pain. *Clin Anat* 2006;19:634-639
 8. Taylor JA, Sartoris DJ, Huang GS, Resnick DL. Painful conditions affecting the first metatarsal sesamoid bones. *Radiographics* 1993;13:817-830
 9. Jahss MH. The sesamoids of the hallux. *Clin Orthop Relat Res* 1981:88-97
 10. Scranton PE Jr, Rutkowski R. Anatomic variations in the first ray: Part II. Disorders of the sesamoids. *Clin Orthop Relat Res* 1980:256-264

선천성 안쪽종자뼈 형성부전과 무혈성 괴사: 증례 보고¹

송윤아¹ · 이승훈¹ · 최찬범² · 주경빈¹ · 류정아³ · 배지윤⁴

종자뼈 무혈성 괴사는 발허리통증의 드문 원인이며 안쪽종자뼈의 선천성 결여 또한 매우 드문 상태로 드물게 보고되는 바이다. 이는 치료방침이 종자뼈 통증을 유발하는 다른 질환과 상반되므로 감별이 필요하다. 아직까지 선천성 종자뼈 형성부전증과 동반된 무혈성괴사는 보고된 바가 없다. 이에 저자들은 방사선사진, 자기공명영상과 초음파상 안쪽종자뼈 형성부전과 진행되는 경화, 골편형성이 관찰된 비외상성 통증으로 발현한 33세 여자 환자에 대해 보고하고자 한다. 이 환자에서 반대편 안쪽종자뼈는 결여되어 있었다.

한양대학교 의과대학 서울병원 ¹영상의학과, ²류마티스내과, ³한양대학교 의과대학 구리병원 영상의학과, ⁴국립경찰병원 병리과