

Case Report

A Ruptured Dermoid Cyst of the Cavernous Sinus Extending into the Posterior Fossa

Seung-Chull Paik, M.D., Choong-Hyun Kim, M.D., Ph.D., Jin-Hwan Cheong, M.D., Ph.D., Jae-Min Kim, M.D., Ph.D.

Department of Neurosurgery, Hanyang University Guri Hospital, Guri, Korea

Supratentorial dermoid cysts are uncommon to develop in the cavernous sinus. We present a ruptured dermoid cyst of the cavernous sinus extending into the posterior fossa. The patient was a 32-year-old female who complained occipital headache, blurred vision, and tinnitus over 4 years. Brain magnetic resonance (MR) imaging revealed an enhanced tumor in the right cavernous sinus extending into the right temporal base and the posterior fossa with findings of ruptured cyst. Surgical resection was performed, and pathological findings were confirmed to be a dermoid cyst. We report a second case with ruptured dermoid cyst of the cavernous sinus extending into the posterior fossa.

Key Words : Cavernous sinus · Dermoid cyst · Posterior fossa · Rupture · Surgery.

INTRODUCTION

Dermoid cyst is rarely found congenital brain tumors, which takes part in only about 1% of all intracranial lesions^{10,11}. Moreover, intracranial dermoid cyst is frequently seen below the tentorium, and its development in the cavernous sinus has been rarely reported in the literature^{1,4,6,7,12,14,16}. To the our best knowledge of English literatures review, two cavernous sinus cases with rupture have been reported^{6,7}. Particularly, the cavernous sinus dermoid cyst extending into the posterior fossa has been also extremely uncommon^{4,6}. A ruptured dermoid cyst of the cavernous sinus extending into posterior fossa has been only reported⁶. With its mass effect or spillage of ruptured particles into the subarachnoid space and ventricles, dermoid cysts could cause deterioration of clinical symptoms. The computed tomography (CT) scans and magnetic resonance (MR) imaging have advantages how to make a diagnosis and manage the ruptured dermoid cyst^{7,21}. In this report, we report a second case of a ruptured dermoid cyst of the cavernous sinus extending into the posterior fossa.

CASE REPORT

A 32-year-old female presented with mild headache in the occipital area over 4 years. Blurred vision in the right eye, right hemifacial clumsiness, tinnitus, and swallowing difficulty were

developed with headache. The severity of symptoms had gradually increased over the last 3 months. In the cerebellar function test, tandem gaits were impaired with accompanying imbalance when rotating her direction. Otherwise, there were no significant neurological deficits. MR imaging showed a heterogenous-signalized huge mass (6.5×4.6×3.3 cm) in the right middle fossa and cavernous sinus extending into the posterior fossa. We also observed multifocal hyperintense lesions in the subarachnoid space on T1-weighted (T1W) MR image suggesting the ruptured particle of dermoid cyst. This mass showed hyperintensity on T2-weighted (T2W) image, hypointense but focal hyperintensity on T1W images, and also hydrocephalus was observed by compression of the adjacent structures including the 4th ventricle, brain stem, and cerebellum (Fig. 1).

Tumor removal performed via subtemporal transtentorial and transpetrosal retrosigmoid approach. We underwent internal debulking of tumor following dural incision, and its content was friable and grayish yellow-colored. The cavernous sinus portion was meticulously removed with preservation of neural structures, and the cavernous segment of the internal carotid artery was seen medially. The part of the tumor in the posterior fossa was excised, however, it was hard to make total excision of tumor because of its severe adhesion to the cranial nerves and brain stem. In the histopathological examination, the specimen was confirmed to be a dermoid cyst (Fig. 2). At a few days after

• Received : December 16, 2013 • Revised : February 18, 2014 • Accepted : April 6, 2014

• Address for reprints : Choong-Hyun Kim, M.D., Ph.D.

Department of Neurosurgery, Hanyang University Guri Hospital, 153 Gyeongchun-ro, Guri 471-701, Korea

Tel : +82-31-560-2322, Fax : +82-31-560-2327, E-mail : kch5142@hanyang.ac.kr

• This is an Open Access article distributed under the terms of the Creative Commons Attribution Non-Commercial License (<http://creativecommons.org/licenses/by-nc/3.0>) which permits unrestricted non-commercial use, distribution, and reproduction in any medium, provided the original work is properly cited.

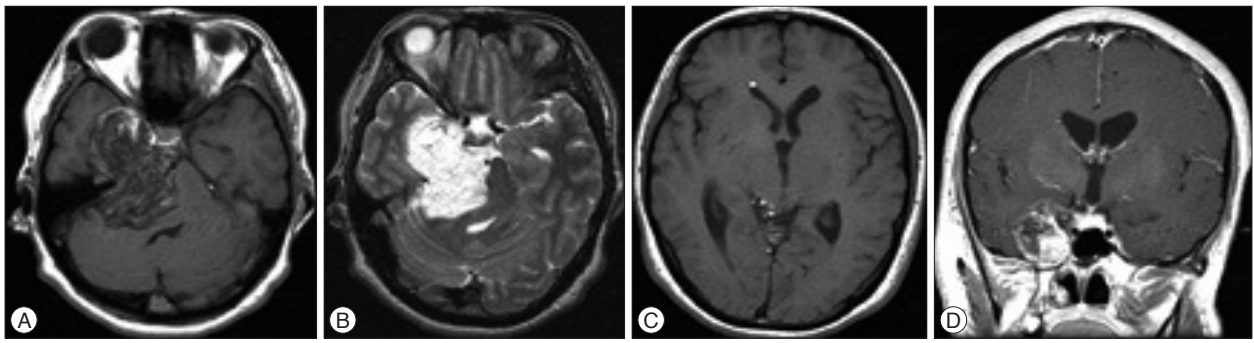


Fig. 1. Preoperative brain magnetic resonance (MR) images. A : Axial T1-weighted MR image reveals a hypointense tumor with partially mixed signal intensity in the right middle and posterior fossa of the skull. B : Axial T2-weighted MR image shows a hyperintense tumor in the skull base including cavernous sinus. C : Axial T1-weighted MR image demonstrates multiple hyperintense lesions in the right lateral ventricle and basal cisterns suggesting the content of cystic rupture. D : Coronal T1-weighted enhanced MR image shows an enhanced tumor in the right cavernous sinus and temporal base.

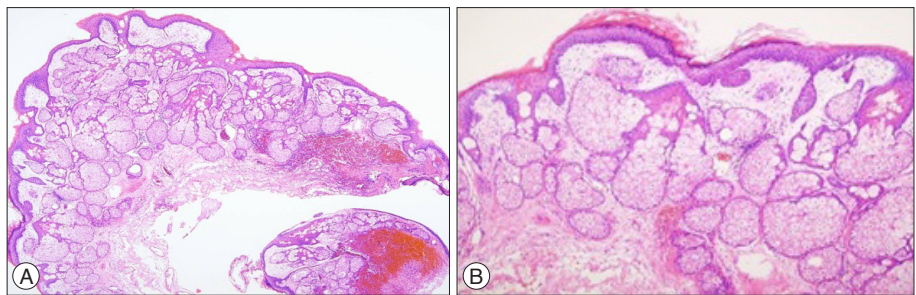


Fig. 2. Photomicrographs show the keratinized stratified epithelium with hair follicles and numerous sebaceous glands suggesting dermoid cyst (H&E staining, A : $\times 40$, B : $\times 100$).

the operation, dysesthesia in the right face and hearing were improved with intact tandem gait. The postoperative course was uneventful.

DISCUSSION

We report a rare case of ruptured cavernous sinus dermoid cyst extending into the posterior fossa. Intracranial dermoid cysts have the component of keratinized squamous epithelium originated from ectoderm composed with dermal materials like hair and sebaceous glands^{3,5,10,11}. They are approximately 3–10 times less frequent than epidermoid tumors. They prefer to be located near the subarachnoid space, sulci or fissures because of the space which has minimal resistance to grow easily, and the midline in the skull base^{12,21}. Supratentorial dermoid cysts were thought to be found more often in the areas of suprasellar, parasellar, temporal, and frontobasal compartment, but in recent studies, infratentorial dermoid cysts are frequently reported^{11,12,17,18,21}. Dermoid cysts are rarely developed in the cavernous sinus and a few cases have been reported as intracranial rather than extradural, interdural dermoid cysts of the cavernous sinus, or parasellar lesions^{1,2,7,12,14,21}. Most reported cases are abutted to venous structures such as the cavernous sinus, and purely interdural dermoid cyst of the cavernous sinus was described by Nakagawa et al.¹⁴. In the radiologic images of our case, it was unclear to define the precise origin from the cavernous sinus or parasellar region. By intraoperative findings, our case seems to be originated in the cavernous sinus, and extended into the posterior fossa.

Pathogenesis of the dermoid cysts in the cavernous sinus is

unclear, however, intracranial intradural dermoid cysts develop near or adherent to large venous structures such as, the cavernous sinus for supratentorial dermoid cysts, and the torcular herophili for infratentorial dermoid cysts¹². Considering that dermal structures or venous channels derive from the mesoderm, this association suggests that these lesions derive from mesodermal nest cells adherent to primitive veins. In an embryo of about 5 mm, the venous drainage of the cranial region is supplied by three superficial pial plexuses surrounding the primary cerebral vesicles⁸. Endothelial pseudopods and pial vessels in the adjacent glia then perforate and penetrate into the nervous tissue, allowing the formation of new intraneural vessels. We speculate that this vascular migration is likely for the development of dermoid cysts adjacent to primitive veins, such as cavernous sinus by the entrapment of mesodermal non-vascular cells¹².

Dermoid tumors of the cavernous region present clinical signs, particularly oculomotor nerve palsy¹⁵. Focal neurological deficits tend to develop lately in the clinical course due to slow growth of these lesions. Cystic rupture like our case may suddenly present and deteriorate clinical symptoms. In our case, the patient presented right hemifacial clumsiness suggesting trigeminal neuropathy and symptoms related to increased intracranial pressure. In the radiologic imaging, characteristic features of dermoid cysts depend on the contents of the lesion. CT scans show hypodense appearance by the fat content in the dermoid cysts on the non-enhanced images^{13,20}. MR imaging is more accurate to diagnosis than CT scans, and usually reveals hyperintensity on T1W image and hypointense to mixed signals on T2W image depending on the contents of dermoid cysts^{2,4,9,12,13,17,19,20}. Al-

though tumor mass was too large to differentiate interdural or intradural tumor in our case, we suspected that tumor was originated from cavernous sinus, based on the findings of coronal MR image. Ruptured particles from the dermoid cyst were detected in the lateral ventricles with hyperintense signals on T1W image.

Because most cases are developed in the young age, we consider that a surgical resection is desirable in majority. In our case, tumor was placed in the right temporal base with originating from the cavernous sinus, and extension into the posterior fossa as previously mentioned. So, we resected a tumor via the combined route by subtemporal transtentorial and transpetrosal retrosigmoid approach. When it extended to the cavernous sinus or hard adhesion to adjacent neurovascular structures, it is better to undertake subtotal removal for avoidance of neurovascular damages^{12,21}.

CONCLUSION

We report an uncommon case of the ruptured dermoid cyst of the cavernous sinus extending into the posterior fossa, and review with pertinent literatures.

References

1. Abdelouafi A, Ousehal A, Gharbi A, Ait Benali S, El Kamar A, Kadiri R : [Cavernous sinus dermoid cyst with unusual parapharyngeal development]. *J Neuroradiol* 27 : 140-143, 2000
2. Akdemir G, Dağlioğlu E, Ergünger MF : Dermoid lesion of the cavernous sinus : case report and review of the literature. *Neurosurg Rev* 27 : 294-298, 2004
3. Bonde V, Goel A, Goel NK : Giant interdural teratoma of the cavernous sinus. *J Clin Neurosci* 15 : 1414-1416, 2008
4. Chen YF, Liu HM, Tu YK : Dermoid cyst as a dumbbell-shaped tumour of the cavernous sinus. *Pediatr Radiol* 33 : 72, 2003
5. Cohen JE, Abdallah JA, Garrote M : Massive rupture of suprasellar dermoid cyst into ventricles. Case illustration. *J Neurosurg* 87 : 963, 1997
6. Dange N, Mahore A, Goel A : Ruptured giant dermoid cyst of the cavernous sinus. *J Clin Neurosci* 17 : 1056-1058, 2010
7. DeMonte F, al-Mefty O : Ruptured dermoid tumor of the cavernous sinus associated with the syndrome of fat embolism. Case report. *J Neurosurg* 77 : 312-315, 1992
8. Hamilton WJ, Boyd JD, Mossman HW : *Human Embryology*, ed 3. Cambridge : W Heifer & Sons, 1962, pp192
9. Hirsch WL Jr, Hryshko FG, Sekhar LN, Brunberg J, Kanal E, Latchaw RE, et al. : Comparison of MR imaging, CT, and angiography in the evaluation of the enlarged cavernous sinus. *AJR Am J Roentgenol* 151 : 1015-1023, 1988
10. Jamjoom AB, Cummins BH : The diagnosis of ruptured intracranial dermoid cysts. *Br J Neurosurg* 3 : 609-612, 1989
11. Kallmes DF, Linda G : Epidermoid and dermoid tumors in Wilkins RH, Rengachary SS (eds) : *Neurosurgery*, ed 2. New York : McGraw-Hill, 1996, Vol 1, pp965-976
12. Lunardi P, Missori P : Supratentorial dermoid cysts. *J Neurosurg* 75 : 262-266, 1991
13. Messori A, Polonara G, Serio A, Gambelli E, Salvolini U : Expanding experience with spontaneous dermoid rupture in the MRI era : diagnosis and follow-up. *Eur J Radiol* 43 : 19-27, 2002
14. Nakagawa K, Ohno K, Nojiri T, Hirakawa K : [Interdural dermoid cyst of the cavernous sinus presenting with oculomotor palsy : case report]. *No Shinkei Geka* 25 : 847-851, 1997
15. North KN, Antony JH, Johnston IH : Dermoid of cavernous sinus resulting in isolated oculomotor nerve palsy. *Pediatr Neurol* 9 : 221-223, 1993
16. Rato RM, Pappamikail LB, Ratilal BO, Luiz CA : Dermoid tumor of the lateral wall of the cavernous sinus. *Surg Neurol Int* 3 : 10, 2012
17. Rubin G, Scienza R, Pasqualin A, Rosta L, Da Pian R : Craniocerebral epidermoids and dermoids. A review of 44 cases. *Acta Neurochir (Wien)* 97 : 1-16, 1989
18. Tada Y, Kannuki S, Kuwayama K, Kouyama Y : [Atypical presentation of a dermoid cyst with porencephaly]. *No Shinkei Geka* 31 : 1215-1220, 2003
19. Venkatesh SK, Phadke RV, Trivedi P, Bannerji D : Asymptomatic spontaneous rupture of suprasellar dermoid cyst : a case report. *Neurol India* 50 : 480-483, 2002
20. Wilms G, Casselman J, Demaerel P, Plets C, De Haene I, Baert AL : CT and MRI of ruptured intracranial dermoids. *Neuroradiology* 33 : 149-151, 1991
21. Yaşargil MG, Abernathey CD, Sarioglu AC : Microneurosurgical treatment of intracranial dermoid and epidermoid tumors. *Neurosurgery* 24 : 561-567, 1989