

# Percutaneous Transluminal Ballooning Angioplasty for Flap Salvage in a Complex Lower Extremity Reconstruction

Seung Yeol Lee, MD, PhD\*  
Ik Hyun Seong, MD†  
Bo Young Park, MD, PhD†

**Summary:** The treatment of lower extremity trauma with extensive soft tissue defects requires a multidisciplinary approach. Following precise bone fixation, appropriate soft tissue reconstruction is a major requisite. We present a case of a severe lower extremity injury caused by an excavator bucket that fell on the patient's foot, which was reconstructed with multiple perforator flaps after concise bone fixation. During the treatment, we repeatedly experienced threatened flaps, which could not be recovered with emergent re-explorations. Although vascular occlusion after a free flap surgery may be rare, it poses a major challenge. It necessitates urgent re-exploration, but there are logistical challenges with providing sufficient resources for endovascular revascularization. We attempted an immediate postoperative angioplasty after the failure of surgical re-exploration as a salvage option and achieved successful flap survival. As the flap completely survived without complications, the patient could walk, with bearing his full weight without the use of any orthosis. Despite the development of new techniques for flap revision, which have increased the possibility of limb salvage, immediate postoperative endovascular revascularization can be considered as a salvage option in cases of a compromised flap. (*Plast Reconstr Surg Glob Open* 2020;8:e3077; doi: [10.1097/GOX.0000000000003077](https://doi.org/10.1097/GOX.0000000000003077); Published online 23 September 2020.)

## INTRODUCTION

Crushing injuries in the lower extremities are devastating phenomena associated with multiple open fractures and extensive soft tissue defects. Early amputation of traumatized lower extremities occasionally improves functional outcomes, but preserving a nonfunctional leg does not guarantee good functionality.<sup>1-3</sup> However, when salvage is attempted, a team effort is required from the beginning of treatment to maintain limb function. Orthopedic and plastic surgeons and interventionists should collaborate to manage these injuries with

an emphasis on several categories, such as limb viability related to vascular problems, stable bone fixation, and soft tissue reconstruction.<sup>4</sup> Here, we present a patient with severe lower extremity trauma caused by an excavator bucket that fell on his left foot. The injury was challenging in terms of decision-making and management; initially, early amputation was considered. During the treatment, we performed multiple perforator flaps for soft tissue reconstruction and repeatedly experienced compromised flaps that could not be recovered with surgical re-exploration. Therefore, we attempted immediate endovascular revascularization after an unsuccessful flap revision process, which has been introduced as a new technique for flap salvage only in some case series of patients with diabetes-related foot problems. Our study focused on the successful collaboration between different teams and the decision to perform immediate endovascular revascularization for a threatened flap. Finally, we were able to salvage the foot and could also achieve good functional results.

From the \*Department of Orthopaedic Surgery, Myongji Hospital, Hanyang University College of Medicine, Seoul, Republic of Korea; and †Department of Plastic and Reconstructive Surgery, School of Medicine, Ewha Womans University, Seoul, Republic of Korea.

Received for publication February 16, 2020; accepted July 7, 2020.

This research was supported by the Basic Science Research Program through the National Research Foundation of Korea (NRF) funded by the Ministry of Science and ICT (NRF-2017R1D1A1B03035452 and NRF-2019R1A2C2010150).

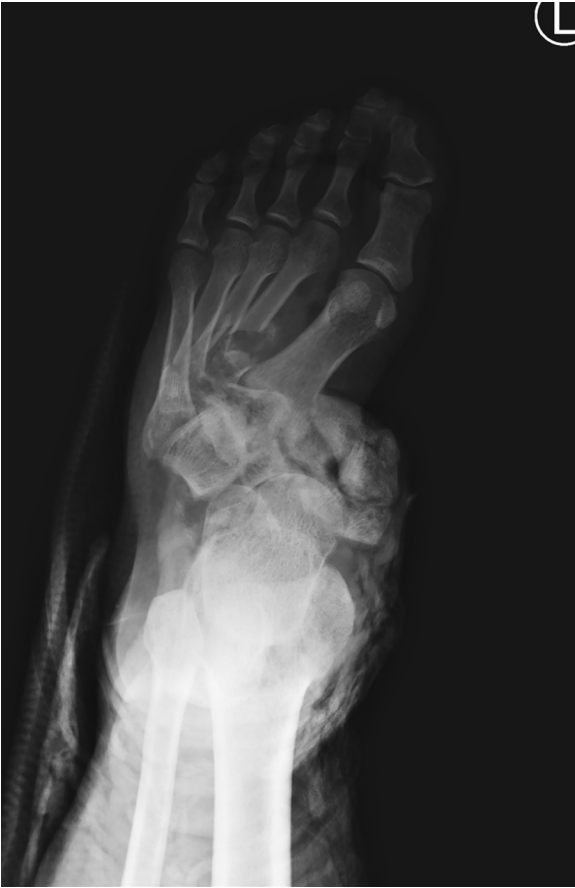Copyright © 2020 The Authors. Published by Wolters Kluwer Health, Inc. on behalf of The American Society of Plastic Surgeons. This is an open-access article distributed under the terms of the [Creative Commons Attribution-Non Commercial-No Derivatives License 4.0 \(CCBY-NC-ND\)](https://creativecommons.org/licenses/by-nc-nd/4.0/), where it is permissible to download and share the work provided it is properly cited. The work cannot be changed in any way or used commercially without permission from the journal.

DOI: [10.1097/GOX.0000000000003077](https://doi.org/10.1097/GOX.0000000000003077)

## CASE REPORT

A 31-year-old man presented to our center following a crushing injury from an excavator bucket that had fallen on his left foot. The injury resulted in multiple fracture

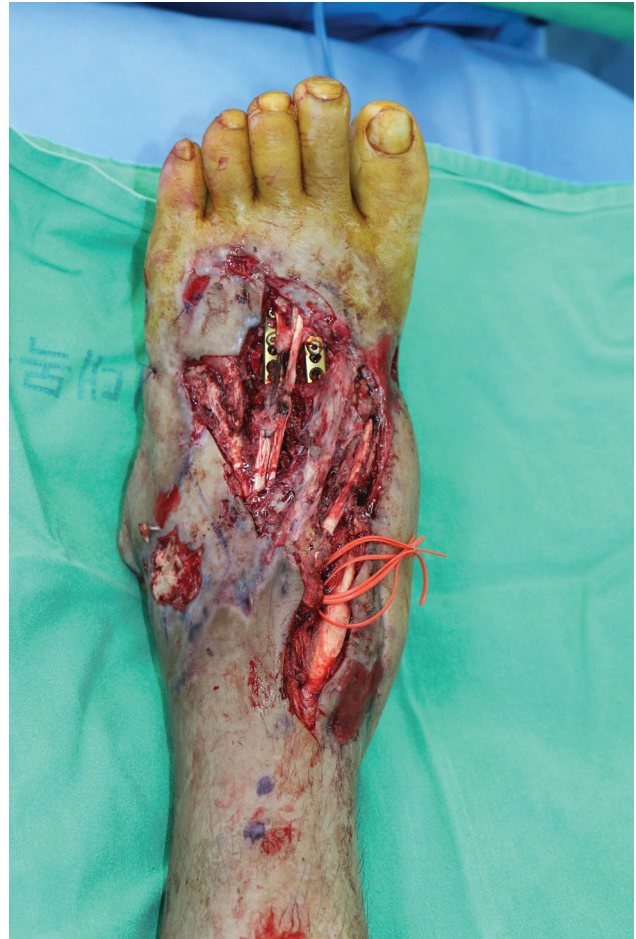**Disclosure:** The authors have no financial interest to declare in relation to the content of this article.



**Fig. 1.** Preoperative radiographic image showing 1<sup>st</sup>–4<sup>th</sup> metatarsal bone fractures with dislocation of Lisfranc, intertarsal, and transverse tarsal joints.

dislocations and a circumferential degloving wound on the midfoot. The midtarsal bones were severely comminuted, and the Lisfranc joint was completely disrupted (Fig. 1). The Mangled Extremity Severity Score (MESS) of the patient was 8 points, indicating the need for a leg amputation. However, our team elected to salvage and preserve the crushed foot after considering multiple factors, including the patient's age and pre-trauma activity levels. We fixed multiple metatarsal base fractures with Kirschner wires (K-wires) to achieve temporary bone fixation. After the bones were fixed, the 10 cm × 21 cm soft tissue defect was covered with a thoracodorsal artery perforator (TDAP) free flap on the day of the injury, mainly on the medial malleolus using the posterior tibial artery as the recipient vessel (end-to-side anastomosis). Ultimately, the flap survived in its entirety without complications.

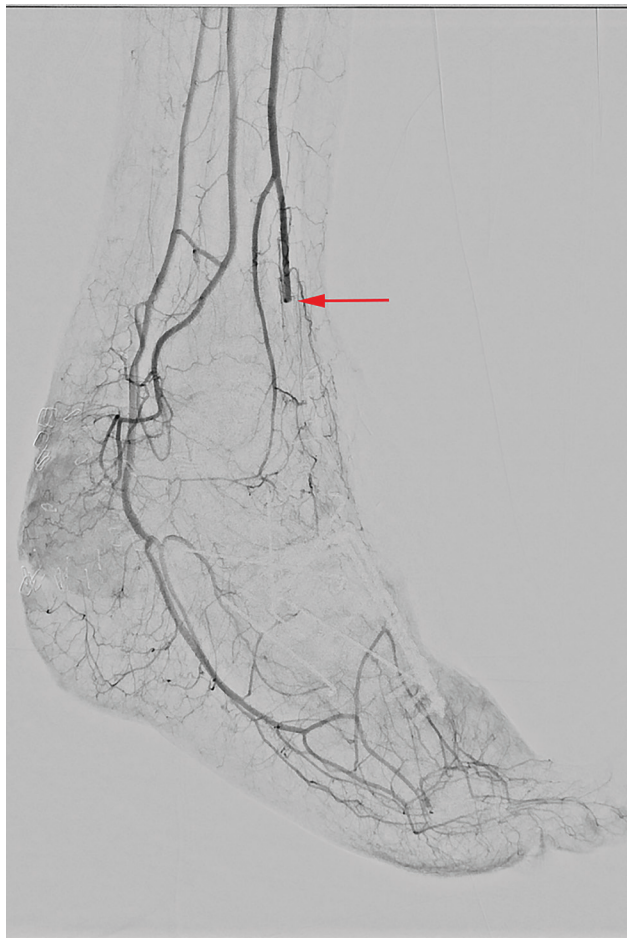
Two months after the initial operation, the patient underwent orthopedic surgery for permanent bone fixation after brisement manipulation of the ankle joint. After the surgery, all internal devices on the foot dorsum were completely exposed (Fig. 2). Consequently, we planned a second soft tissue reconstruction with an anterolateral thigh (ALT) free flap using the anterior tibial artery (ATA) as a recipient vessel. To cover the defect, a 10 cm × 8 cm ALT flap was harvested and prepared for microanastomosis to the ATA (end-to-side pattern). However, sudden weakening



**Fig. 2.** Photograph displaying a 6 cm × 14 cm defect in the foot dorsum and exposure of the fixator with the previous thoracodorsal artery perforator free flap at the medial malleolus.

of the Doppler sound was noted during preparation of the recipient vessel, although there were no specific findings on preoperative computed tomography (CT) angiography. As such, we performed massive heparin irrigation and anastomosed after confirming the recovery of blood flow. Once anastomosis was completed, the flap repeatedly showed compromised signs with a weak Doppler signal. The flap was intraoperatively revised in an end-to-end pattern, and reperfusion was attempted using a 3-mm Fogarty catheter. Subsequent to the final flap recovery, we completed the operation. After a few days, the flap became completely unviable. We planned another TDAP free flap 10 days later. A vessel proximal to the previous anastomosis site was chosen as the recipient vessel. After removal of the compromised flap, we observed anastomosed vessels filled with thrombosis, which showed a weak arterial pulsation. Accordingly, we attempted a thrombectomy of the ATA using a 3-mm Fogarty catheter and massive intraluminal heparin irrigation before the anastomosis. Observation of intraoperative Doppler revealed resolution of thrombosis. Thus, we microanastomosed it to the ATA (end-to-end pattern) in the proximal portion after confirming a reliable Doppler signal. At the end of the operation, the flap again turned pale in color, and a sudden disappearance of the Doppler

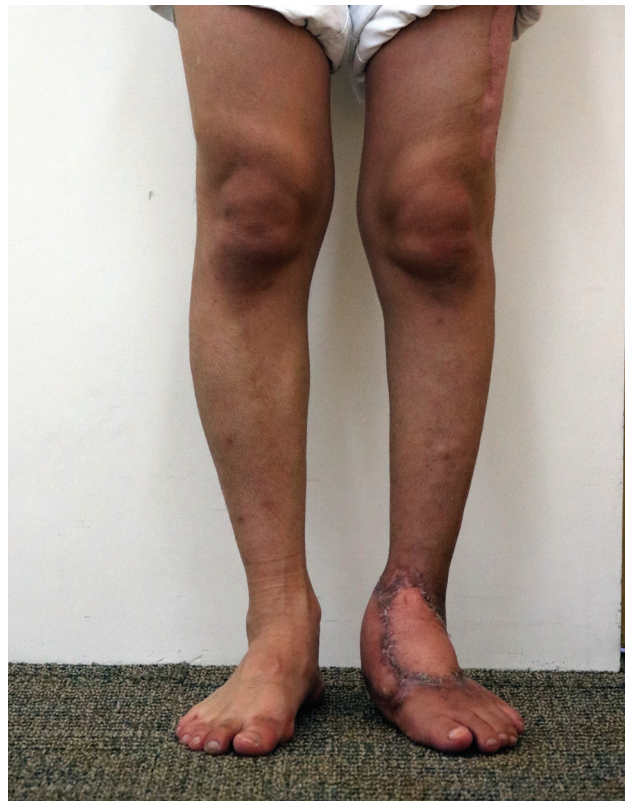



**Fig. 3.** Angiographic image showing occlusion of the distal anterior tibial artery.

signal was noted. Despite our repeated intraoperative revision procedures, the compromised flap recovered instantly and continued to deteriorate, irrespective of our efforts. As there were no alternative options, we decided to perform a postoperative percutaneous transluminal angioplasty (PTA). The patient was immediately sent to the intervention room. A contralateral antegrade approach was chosen, and a long 5-Fr sheath was inserted via the right common femoral artery by the intervention radiologist. Angiography findings showed occlusion of the distal ATA with non-visualization of flow to the flap (Fig. 3). Initially, the intervention radiologist attempted an aspiration thrombectomy with 4- and 5-Fr catheters. Although recovery from the weak flow to the flap occurred, complete improvement could not be achieved. Additional angioplasty was performed by carefully passing a long 3-mm balloon catheter through the distal ATA. The ATA was dilated with a low-pressure, compliant balloon for an extended period immediately before the anastomosis. Eventually, a significant improvement in flow to the ATA was observed, and the flap became pinkish with a loud pulsatile Doppler signal. Finally, the flap survived completely without complications (Fig. 4).

The patient was able to start rehabilitation therapy, including non-weight-bearing activity for 6 weeks



**Fig. 4.** Postoperative photograph of the patient's leg 7 months after surgery, showing a completely survived flap without complications.

following surgery and protected weight-bearing activity for the subsequent 4 weeks, followed by formal physical therapy. Seven months after the injury, he was able to walk, bearing his full weight without any help from crutches or orthosis. Regarding functional outcomes, he was able to touch the floor with his left heel at the time of the initial contact during gait cycles. The American Orthopedic Foot and Ankle Score of this patient was 83, and his Foot and Ankle Disability Index score was 102.

## DISCUSSION

Severe lower extremity trauma is an infrequent injury, which leads to difficulty in deciding between early amputation or salvage of the leg. The decision to salvage versus amputate the limb in patients with major injuries should be individualized depending on the condition of the limb, the patient's general medical condition, and the surgeon's experience.<sup>5-9</sup> In our case, we attempted to salvage the patient's leg by carefully following a multidisciplinary team approach that included various attempts at soft tissue reconstruction. Although we adequately planned using CT angiography and selected appropriate recipient vessels outside the trauma zone, arterial insufficiency occurred each time, which could not be resolved with conventional procedures. Consequently, the attempt to reconstruct the foot dorsum failed and necessitated a secondary procedure. During the second free flap reconstruction (which was done a few days after the first), we approached the site carefully and chose an immediately

proximal recipient vessel. However, despite our attempts, including changing the anastomosis site and patterns, the previously traumatized artery could not be recovered.

Although immediate re-exploration of the anastomotic site remains the gold standard in flap revision, we considered various flap salvage methods, including new techniques that have been recently introduced in the literature, because we could not salvage the flap through traditional methods. Along with flap perfusion, the following techniques have shown positive effects on salvage rates: 1) postoperative leeches in venous congestion, 2) adjunctive administration of thrombolytic agents during the salvage procedure, 3) thrombectomy using a Fogarty catheter, and 4) use of an arteriovenous fistula.<sup>10–12</sup> Moreover, there have been a few reports of minimally invasive free flap salvage techniques. Catheter-directed infusion, mechanical thrombectomy, and use of thrombolytic agents have been attempted for salvage.<sup>13</sup>

Given these considerations, we made the extreme choice to attempt endovascular revascularization, which is reported in the literature as a supplementary measure for flap salvage. Rather, it has become the first line of management for peripheral artery occlusion in diabetic patients with an ulcer or critical limb ischemia.<sup>14,15</sup> Its usefulness can be indicated by any of the following characteristics: ankle-brachial index (ABI) < 0.8, ankle systolic pressure < 80 mm Hg or systolic toe pressure < 40 mm Hg, or transcutaneous oxygen tension (Tc)2 < 40 mm Hg, along with at least 1 imaging examination demonstrating flow in an atherosclerotic lesion below the inguinal ligament on any imaging modality.<sup>16,17</sup> Endovascular revascularization is safe even in the absence of contraindications for patients who show stenoses or occlusions and can be repeated following re-occlusions or a bypass failure.<sup>14,15</sup> Improvements in the endovascular technique have resulted in similar outcomes compared to the surgical bypass in limb salvage rates.<sup>15</sup> The past decade has witnessed a paradigm shift toward endovascular revascularization.

The combination of endovascular revascularization and free flap salvage has been established only in a small case series on the treatment of diabetic feet.<sup>12,13</sup> For instance, Anavekar et al. reported delayed flap salvage after endovascular revascularization<sup>18</sup> with ballooning and urokinase.<sup>18</sup> Kim et al. reported 2 cases of diabetic flap salvage with immediate postoperative PTA.<sup>19</sup> To the best of our knowledge, immediate endovascular revascularization with PTA for a compromised flap in a severely traumatized leg has not been attempted before.

Free flap salvage with endovascular revascularization may be a valuable tool during reconstruction, and its role warrants exploration. Although thrombectomy or anastomotic flap revision in a timely manner can result in a reliable flap salvage rate, the technique is significantly better than operative exploration for several reasons. A return to the operating room that may have resulted in major anesthetic complications was prevented by employing local anesthetics in the angiography room. An endoluminal approach avoided the reopening of wounds that could potentially have resulted in postoperative complications. The approach can be accomplished without making any

incision and allows for a precise visualization of problematic lesions, thus becoming a no-loss proposition for patients with postoperative arterial problems. Although the method has some consequences, such as difficulty in precisely identifying problematic sites, difficulty in controlling ballooning locations, and exposure to radiation, if applied appropriately, flap salvage can be achieved with minimal morbidity. The results of the present case promise a significant alternative option for flap salvage in carefully selected patients, although further studies are necessary to verify the reliability of the method.

**Bo Young Park, MD, PhD**

Department of Plastic and Reconstructive Surgery  
School of Medicine  
Ewha Womans University  
Seoul, Republic of Korea  
E-mail: by.park@ewha.ac.kr

## REFERENCES

1. Yazar S, Lin CH, Wei FC. One-stage reconstruction of composite bone and soft-tissue defects in traumatic lower extremities. *Plast Reconstr Surg*. 2004;114:1457–1466.
2. Elsharawy MA, Maher K, Elsaid AS. Limb salvage in a child with severely injured mangled lower extremity and muscle rigor. *Vascular*. 2012;20:321–324.
3. Schiro GR, Sessa S, Piccioli A, et al. Primary amputation vs limb salvage in mangled extremity: a systematic review of the current scoring system. *BMC Musculoskelet Disord*. 2015;16:372.
4. Xiong L, Gazyakan E, Wähmann M, et al. Microsurgical reconstruction for post-traumatic defects of lower leg in the elderly: a comparative study. *Injury*. 2016;47:2558–2564.
5. Tampe U, Weiss RJ, Stark B, et al. Lower extremity soft tissue reconstruction and amputation rates in patients with open tibial fractures in Sweden during 1998–2010. *BMC Surg*. 2014;14:80.
6. Langer V. Management of major limb injuries. *Scientific World Journal*. 2014;2014:640430.
7. Johansen K, Daines M, Howey T, et al. Objective criteria accurately predict amputation following lower extremity trauma. *J Trauma*. 1990;30:568–572; discussion 572.
8. Jain A, Glass GE, Ahmadi H, et al. Delayed amputation following trauma increases residual lower limb infection. *J Plast Reconstr Aesthet Surg*. 2013;66:531–537.
9. Hansen ST Jr. The type-IIIC tibial fracture. Salvage or amputation. *J Bone Joint Surg Am*. 1987;69:799–800.
10. Eser C, Gencel E, Yavuz M, et al. Salvage of a free osteocutaneous fibula flap by creating a distal arteriovenous fistula in facial reconstruction. *Int J Oral Maxillofac Surg*. 2015;44:1095–1098.
11. Gröbe A, Michalsen A, Hanken H, et al. Leech therapy in reconstructive maxillofacial surgery. *J Oral Maxillofac Surg*. 2012;70:221–227.
12. Kubo T, Yano K, Hosokawa K. Management of flaps with compromised venous outflow in head and neck microsurgical reconstruction. *Microsurgery*. 2002;22:391–395.
13. Yii NW, Evans GR, Miller MJ, et al. Thrombolytic therapy: what is its role in free flap salvage? *Ann Plast Surg*. 2001;46:601–604.
14. Brownrigg JR, Apelqvist J, Bakker K, et al. Evidence-based management of PAD & the diabetic foot. *Eur J Vasc Endovasc Surg*. 2013;45:673–681.
15. Schamp KB, Meerwaldt R, Reijnen MM, et al. The ongoing battle between infrapopliteal angioplasty and bypass surgery for critical limb ischemia. *Ann Vasc Surg*. 2012;26:1145–1153.
16. Abdelhamid MF, Davies RS, Rai S, et al. Below-the-ankle angioplasty is a feasible and effective intervention for critical leg ischaemia. *Eur J Vasc Endovasc Surg*. 2010;39:762–768.

17. Flumignan CDQ, Amaral FCF, Flumignan RLG, et al. Angioplasty and stenting for below the knee ulcers in diabetic patients: protocol for a systematic review. *Syst Rev.* 2018;7:228.
18. Anavekar NS, Lim E, Johnston A, et al. Minimally invasive late free flap salvage: indications, efficacy and implications for reconstructive microsurgeons. *J Plast Reconstr Aesthet Surg.* 2011;64:1517–1520.
19. Kim JY, Choi HG, Uhm KI, et al. Salvage of a free flap using post-operative percutaneous angioplasty in patients with diabetic foot ulcers. *Arch Plast Surg.* 2014;41:788–790.