

# Adult Idiopathic Renal Fanconi Syndrome: A Case Report

Dae Jin Park<sup>1</sup>, Ki-Seok Jang<sup>2</sup>, Gheun-Ho Kim<sup>1</sup>

Departments of <sup>1</sup>Internal Medicine and <sup>2</sup>Pathology, Hanyang University College of Medicine, Seoul, Korea

Received: February 7, 2019

Accepted: February 20, 2019

Corresponding Author: Gheun-Ho Kim MD, PhD,  
Department of Internal Medicine, Hanyang University  
College of Medicine, 222-1 Wangsimni-ro,  
Seongdong-gu, Seoul 04763, Korea  
Tel: +82-2-2290-8318  
Fax: +82-2-2298-9183  
E-mail: kimgh@hanyang.ac.kr

Renal Fanconi syndrome (RFS) is caused by generalized proximal tubular dysfunction and can be divided into hereditary and acquired form. Adult-onset RFS is usually associated with drug toxicity or systemic disorders, and modern molecular genetics may explain the etiology of previous idiopathic cases of RFS. Here, we report the case of a 52-year-old woman with RFS whose etiology could not be identified. She presented with features of phosphaturia, renal glucosuria, aminoaciduria, tubular proteinuria, and proximal renal tubular acidosis. Her family history was unremarkable, and previous medications were nonspecific. Her bone mineral density was compatible with osteoporosis, serum intact parathyroid hormone level was mildly elevated, and 25(OH) vitamin D level was insufficient. Her blood urea nitrogen and serum creatinine levels were 8.4 and 1.19 mg/dL, respectively (estimated glomerular filtration rate, 53 mL/min/1.73 m<sup>2</sup>). Percutaneous renal biopsy was performed but revealed no specific renal pathology, including mitochondrial morphology. No mutation was detected in *EHHADH* gene. We propose the possibility of involvement of other genes or molecules in this case of adult RFS.

**Key Words:** EHHADH gene, Idiopathic Fanconi syndrome, Osteoporosis, Phosphaturia, Renal tubular acidosis

This is an Open Access article distributed under the terms of the Creative Commons Attribution Non-Commercial License (<http://creativecommons.org/licenses/by-nc/4.0/>) which permits unrestricted non-commercial use, distribution, and reproduction in any medium, provided the original work is properly cited.

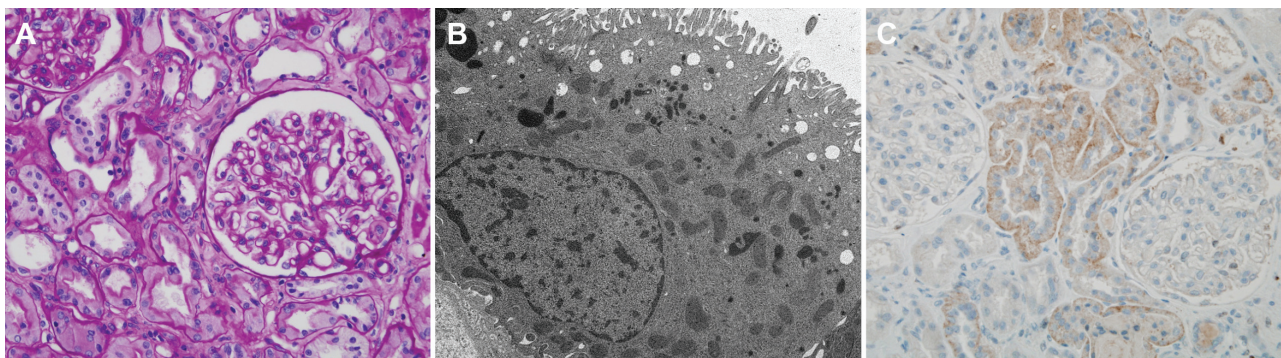
## Introduction

Fanconi syndrome is caused by generalized proximal tubular dysfunction and manifested by phosphaturia, renal glucosuria, aminoaciduria, tubular proteinuria, and proximal renal tubular acidosis (RTA). It is associated with systemic features in many cases<sup>1</sup>, and its renal-limited form is called renal Fanconi syndrome (RFS).

The etiology of RFS includes inherited and acquired disorders, and RFS diagnosed in adults is most commonly associated with drug toxicity<sup>2</sup>. However, idiopathic adult-onset RFS has been reported<sup>3</sup>. With the advances in molecular genetics, three genetic forms of RFS have been identified, namely Fanconi renotubular syndrome (FRTS) types 1-3<sup>1</sup>. Previously, these were considered idiopathic disorders.

Although the underlying gene is yet to be identified, FRTS1 is inherited in an autosomal dominant fashion and associated with progressive chronic kidney disease (CKD)<sup>4</sup>. FRTS2 is characterized by phosphate wasting and rickets, and caused by a mutation in *SLC34A1*, encoding the phosphate transporter NaPi-IIa<sup>5</sup>. It has so far been described only in two siblings<sup>6</sup> and may not be a true RFS in those cases because RTA was not present<sup>7</sup>.

On the other hand, FRTS3 is the prototype of RFS characterized by no kidney failure<sup>1</sup>. Its autosomal dominant inheritance was described in a five-generation family<sup>8</sup>, and the heterozygous missense mutation in the *EHHADH* gene was identified<sup>9</sup>. However, possibilities remain that other genes and molecules are involved in the pathogenesis of RFS or FRTS. Furthermore, adult idiopathic cases or spontaneous mutations in RFS are elusive. Here, we report



**Fig. 1.** Kidney biopsy findings. A: Light microscopy shows normal glomerular and tubulointerstitial architectures. B: Electron microscopy reveals unremarkable mitochondrial ultrastructure. C: Immunohistochemistry for Na/K-ATPase  $\alpha$ 1 subunit shows intact labeling along the basolateral membrane of the proximal tubule.

the case of a 52-year-old woman with RFS whose etiology could not be identified.

### Case Report

A 52-year-old woman was admitted to our hospital for further evaluation of kidney disease. She was previously healthy except for an incidentally found osteoporosis during the previous year's checkup. Her bone mineral density was aggravated at that year's follow-up, so she visited a local hospital, where she was diagnosed as having Fanconi syndrome. The following amino acids were elevated in the 24-h urine collection: taurine, aspartic acid, threonine, serine, asparagine, glutamine, glycine, alanine, citrulline,  $\alpha$ -aminobutyric acid, valine, cysteine, isoleucine, leucine, tyrosine, phenylalanine, ornithine, lysine, l-methylhistidine, histidine, and arginine. Her family history was unremarkable. In the previous last year, she took some herbal medicine as a lipid-lowering agent for approximately 1 year. She was unmarried and did missionary work in foreign countries. She complained of no urinary symptoms.

Her blood pressure was 100/60 mmHg, and physical examination results were normal. Urinalysis revealed the following: specific gravity of 1.024, pH 7.0, albumin +, glucose ++, RBC 20-29/HPF, and WBC 0-2/HPF. The following laboratory values were obtained: serum calcium, 8.9 mg/dL; phosphorus, 1.9 mg/dL; uric acid, 0.8 mg/dL; magnesium, 2.8 mg/dL; cholesterol, 202 mg/dL; protein, 6.9 g/dL; albumin, 4.2 g/dL; BUN, 8.4 mg/dL; creatinine, 1.19 mg/dL; glucose, 104 mg/dL; and HbA1c, 4.7%. Her estimated glomerular filtration rate (eGFR) was 53 mL/min/

1.73 m<sup>2</sup>, calculated using the Chronic Kidney Disease Epidemiology Collaboration (CKD-EPI) equation. The following values were obtained in 24-hour urine monitoring: protein, 2935 mg; albumin, 153 mg; sodium, 142 mmol; potassium, 59 mmol; chloride, 132 mmol; calcium, 428 mg; magnesium, 83.5 mg; uric acid, 455 mg; glucose, 20797 mg; and creatinine, 1.0 g. The urine  $\beta$ 2-microglobulin level was >20,000  $\mu$ g/L.

Fractional excretions of calcium, phosphorus, magnesium, and uric acid were 3.4%, 43.1%, 2.2%, and 63.4%, respectively. The serum intact parathyroid hormone (PTH) level was 74.5 pg/mL, and the 25(OH) vitamin D level was 20.4 ng/mL. Her bone mineral density was compatible with osteoporosis. Bone scintigraphy revealed old multiple rib fractures and diffusely increased whole-body bone uptake, which are suggestive of metabolic bone disease.

The serum concentrations of sodium, potassium, chloride, and total CO<sub>2</sub> were 139, 3.6, 114, and 19.0 mmol/L, respectively. Arterial blood gas analysis revealed the following values: pH, 7.30; PaCO<sub>2</sub>, 34.8 mmHg; PaO<sub>2</sub>, 118 mmHg; and HCO<sub>3</sub><sup>-</sup>, 16.6 mmol/L. The urine sodium, potassium, chloride, and creatinine concentrations were 63 mmol/L, 21 mmol/L, 80 mmol/L, and 40 mg/dL, respectively. The fractional excretion of bicarbonate was elevated from 0.8% (at urine pH 6.8) to 15.3% (at urine pH 7.53) in response to the intravenous sodium bicarbonate infusion. The urine-blood PCO<sub>2</sub> gradient reached 53 mmHg.

Percutaneous renal biopsy was performed but did not reveal any specific renal pathology (Fig. 1). Glomerular and tubulointerstitial architectures were normal, and the mitochondrial ultrastructure was unremarkable. In addition,

immunostaining for the Na/K-ATPase  $\alpha$ 1 subunit was intact along the basolateral membrane of the proximal tubule. We performed a mutation analysis and detected no mutation in the *EHHADH* gene. She was discharged with a prescription of NaHCO<sub>3</sub> and calcitriol.

## Discussion

We present an adult case of RFS in which no etiology could be identified. The patient was 52 years old when she was diagnosed, and osteoporosis was the only manifestation associated with her RFS. She had typical features of generalized proximal tubular dysfunction, and proximal RTA was demonstrated by the bicarbonate loading test.

As expected, metabolic bone disease was the predominant feature in this case. Vitamin D insufficiency, and renal wasting of phosphorus and calcium were linked to osteoporosis and increased intact PTH level. Calcitriol was administered but not bisphosphates because of several reports of zoledronate-induced RFS<sup>10-12</sup>.

Drug-induced nephrotoxicity would be the most probable cause of adult-onset RFS<sup>3</sup>. In our case, a certain herbal medicine taken for lipid lowering could be the culprit of the RFS because aristolochic acid-associated nephropathy was reported to be associated with RFS<sup>13</sup>. However, the renal tissues and ultrastructure revealed no pathology. We believe that she took natural remedies only.

Systemic diseases such as monoclonal gammopathy and legionella pneumonia were reported to be complicated by RFS<sup>14,15</sup>. These possibilities were excluded using our clinical and laboratory examinations.

Then, genetic causes of RFS can be suspected. Our case was compatible with isolated RFS because it was not accompanied by systemic disorders<sup>1</sup>. However, previously known FRTS types 1, 2, and 3 were unlikely because of the lack of information on family history and evidence of rickets. In particular, the diagnosis of FRTS3 was excluded by performing a mutation analysis of the *EHHADH* gene.

We also tested whether the basolateral expression of Na/K-ATPase was deficient in the proximal tubule because it acts as the primary drive for solute transport along the nephron<sup>16</sup>. However, we found no abnormality of the Na/K-ATPase  $\alpha$ 1 subunit immunoreactivity. Finally, we suggest the possibility of spontaneous mutation of previously

unknown genes involving the ion transport in the proximal tubule. Whole-exome sequencing might be useful for identifying another RFS-related mutation in our patient.

## Conflict of interest

The authors declare no relevant financial interests.

## Acknowledgment

We thank Prof. Hae Il Cheong at Seoul National University for the mutation analysis of the *EHHADH* gene.

## References

1. Klootwijk ED, Reichold M, Unwin RJ, Kleta R, Warth R, Bockenhauer D: Renal Fanconi syndrome: taking a proximal look at the nephron. *Nephrol Dial Transplant* 30:1456-1460, 2015
2. Dalmak S, Erek E, Serdengeci K, Okar I, Ulku U, Basaran M: A case study of adult-onset hypophosphatemic osteomalacia with idiopathic fanconi syndrome. *Nephron* 72:121-122, 1996
3. Hall AM, Bass P, Unwin RJ: Drug-induced renal Fanconi syndrome. *QJM* 107:261-269, 2014.
4. Lichter-Konecki U, Broman KW, Blau EB, Konecki DS: Genetic and physical mapping of the locus for autosomal dominant renal Fanconi syndrome, on chromosome 15q15.3. *Am J Hum Genet* 68:264-268, 2001
5. Magen D, Berger L, Coady MJ, Ilivitzki A, Militianu D, Tieder M, Selig S, Lapointe JY, Zelikovic I, Skorecki K: A loss-of-function mutation in NaPi- IIa and renal Fanconi's syndrome. *N Engl J Med* 362:1102-1109, 2010
6. Tieder M, Arie R, Modai D, Samuel R, Weissgarten J, Liberman UA. Elevated serum 1,25-dihydroxyvitamin D concentrations in siblings with primary Fanconi's syndrome. *N Engl J Med* 319:845-849, 1988
7. Kleta R. Fanconi or not Fanconi? Lowe syndrome revisited. *Clin J Am Soc Nephrol* 3:1244-1245, 2008
8. Tolaymat A, Sakarcan A, Neiberger R: Idiopathic Fanconi syndrome in a family. Part I. Clinical aspects. *J Am Soc Nephrol* 2:1310-1317, 1992
9. Klootwijk ED, Reichold M, Helip-Wooley A, Tolaymat A, Broeker C, Robinette SL, Reinders J, Peindl D, Renner K, Eberhart K, Assmann N, Oefner PJ, Dettmer K,

- Sterner C, Schroeder J, Zorger N, Witzgall R, Reinhold SW, Stanescu HC, Bockenbauer D, Jaureguiberry G, Courtneidge H, Hall AM, Wijeyesekera AD, Holmes E, Nicholson JK, O'Brien K, Bernardini I, Krasnewich DM, Arcos-Burgos M, Izumi Y, Nonoguchi H, Jia Y, Reddy JK, Ilyas M, Unwin RJ, Gahl WA, Warth R, Kleta R: Mistargeting of peroxisomal EHHADH and inherited renal Fanconi's syndrome. *N Engl J Med* 370:129-138, 2014
10. Yoshinami T, Yagi T, Sakai D, Sugimoto N, Imamura F: A case of acquired Fanconi syndrome induced by zoledronic acid. *Intern Med* 50:1075-1079, 2011
  11. Torimoto K, Okada Y, Arai T, Mori H, Tanaka Y: A case of zoledronate-induced tubulointerstitial nephritis with Fanconi syndrome. *Endocr J* 59:1051-1056, 2012
  12. Gutiérrez Sánchez MJ, Petkov Stoyanov V, Pedraza Cezón L, Martín Navarro JA: Kidney failure caused by tubular interstitial nephropathy with Fanconi syndrome after treatment with zoledronic acid. *Nefrologia*. 37:660-661, 2017
  13. Lee S, Lee T, Lee B, Choi H, Yang M, Ihm CG, Kim M: Fanconi's syndrome and subsequent progressive renal failure caused by a Chinese herb containing aristolochic acid. *Nephrology* 9:126-129, 2004
  14. Ma CX, Lacy MQ, Rompala JF, Dispenzieri A, Rajkumar SV, Greipp PR, Fonseca R, Kyle RA, Gertz MA: Acquired Fanconi syndrome is an indolent disorder in the absence of overt multiple myeloma. *Blood* 104:40-42, 2004
  15. Koda R, Itoh R, Tsuchida M, Ohashi K, Iino N, Takada T, Narita I: Legionella Pneumonia Complicated with Acquired Fanconi Syndrome. *Intern Med* 57:2975-2980, 2018
  16. Horita S, Nakamura M, Suzuki M, Satoh N, Suzuki A, Homma Y, Nangaku M: The role of renal proximal tubule transport in the regulation of blood pressure. *Kidney Res Clin Pract* 36:12-21, 2017